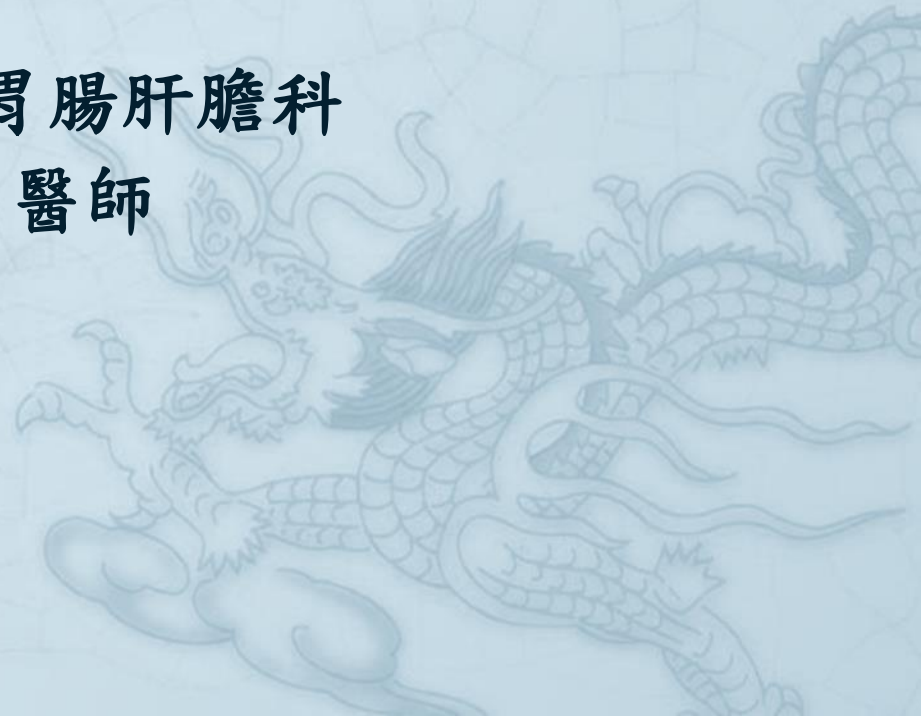

Physical examination in Gastroenterology


馬偕醫院 胃腸肝膽科
林慶忠醫師



腹部身體檢查




- ◆ **Anatomy**
- ◆ Techniques of Examination
 - ◆ General Approach
 - ◆ Inspection
 - ◆ Auscultation
 - ◆ Percussion
 - ◆ Palpation
- ◆ Special Maneuver

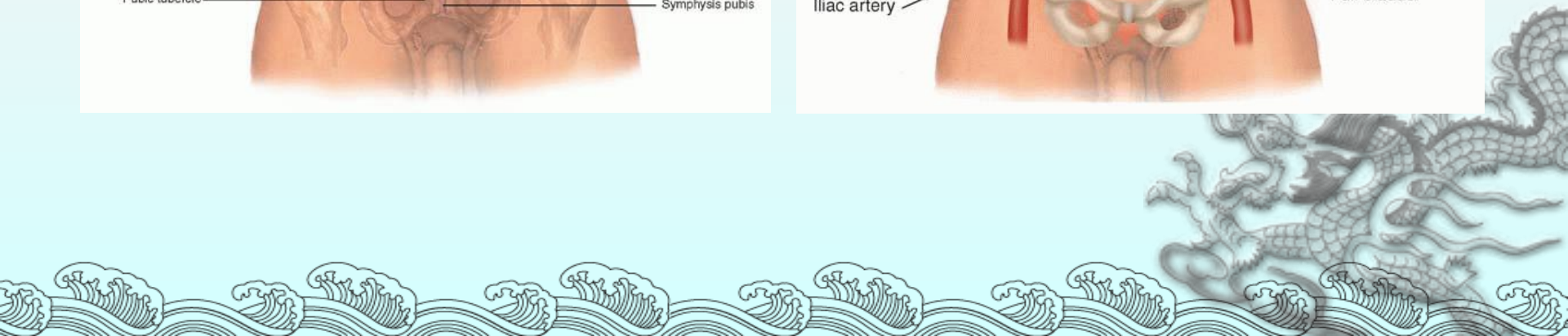
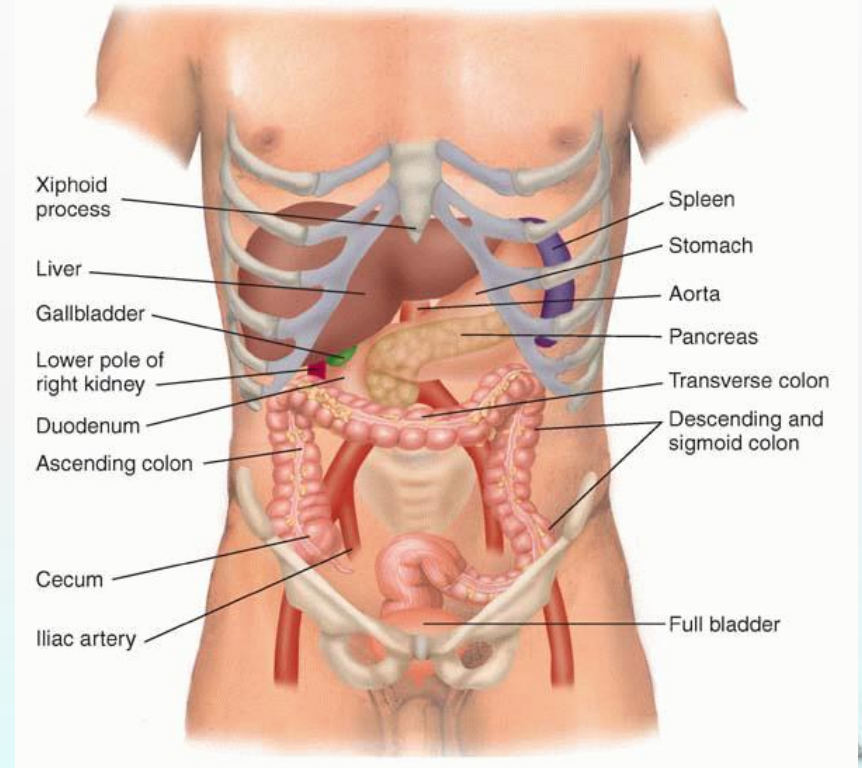
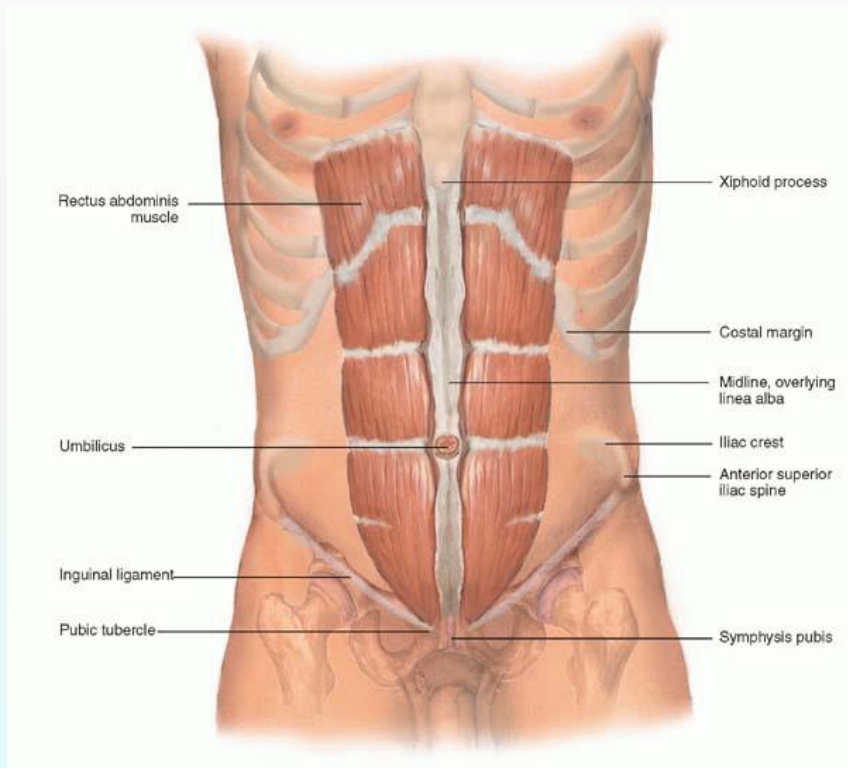


Equipment

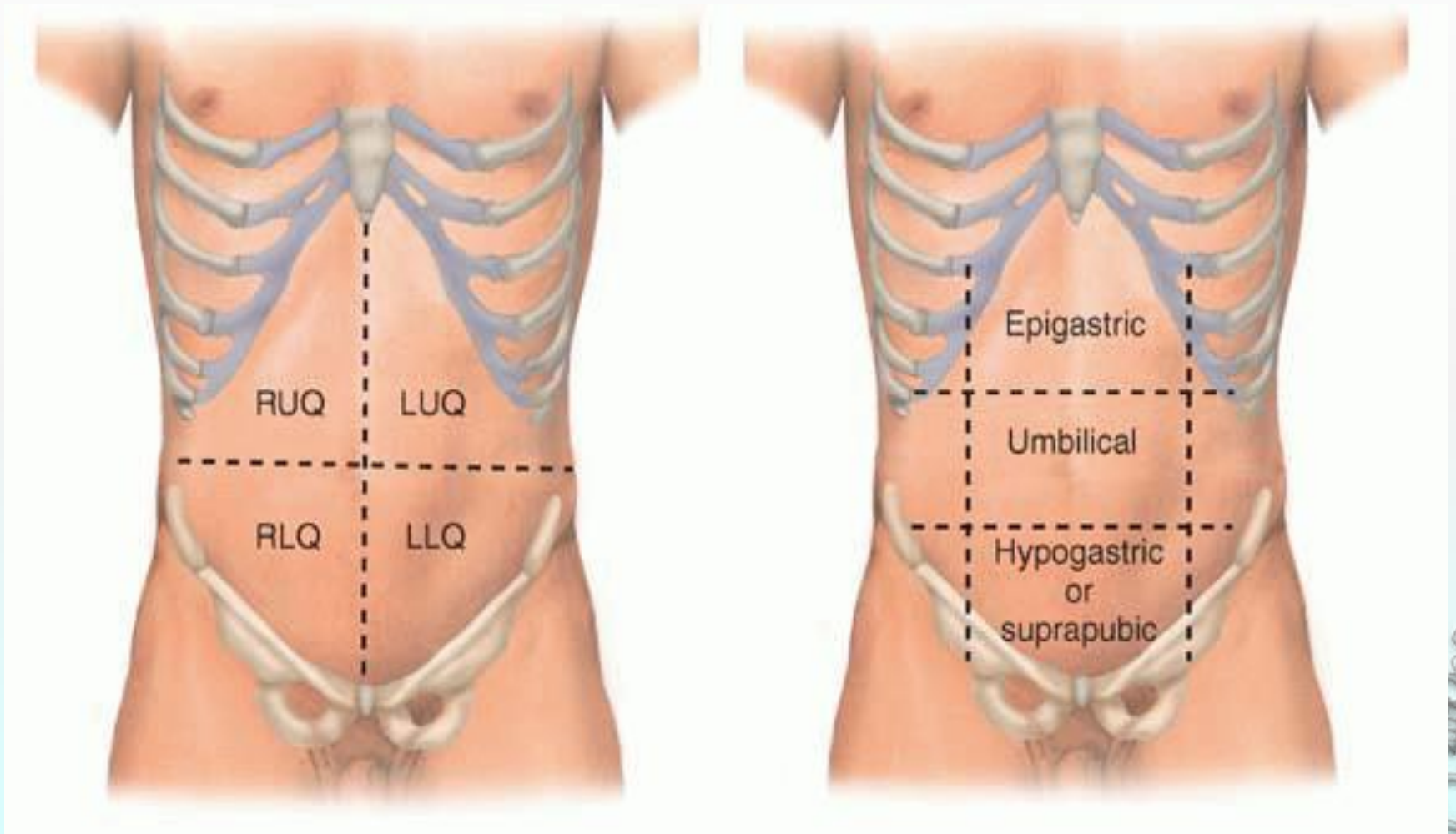
- ◆ Stethoscope
- ◆ Centimeter ruler and non-stretchable measuring tape
- ◆ Marking pen
- ◆ Glove
- ◆ Lubricant
- ◆ Tissues
- ◆ Occult blood testing card and Hemoccult developer



ANATOMY AND PHYSIOLOGY

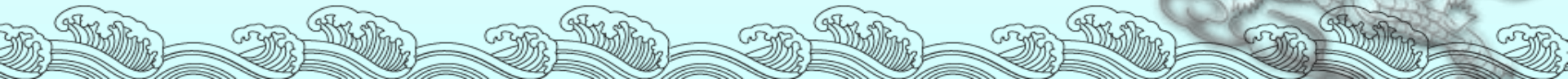


Imaginary lines




腹部身體檢查

- ◆ Anatomy
- ◆ Techniques of Examination
 - ◆ **General Approach**
 - ◆ Inspection
 - ◆ Auscultation
 - ◆ Percussion
 - ◆ Palpation
- ◆ Special Maneuver




General Approach

- ◆ 良好光線 + 病人放鬆 + 適當暴露
- ◆ 病人平臥 + 手勿高舉 + 膝蓋微曲
- ◆ 慢慢檢查 + 隨時修正 + 保持溫暖
- ◆ 保持對話 + 隨時說明 + 轉移注意
- ◆ 由遠而近 + 由輕而重 + 最後壓痛
- ◆ 由病人自己指出痛點或病灶
- ◆ 怕癢者可將病患的手放在醫師之手下



腹部身體診察

- ◆ Anatomy
- ◆ Techniques of Examination
 - ◆ General Approach
 - ◆ **Inspection**
 - ◆ Auscultation
 - ◆ Percussion
 - ◆ Palpation
- ◆ Special Maneuver



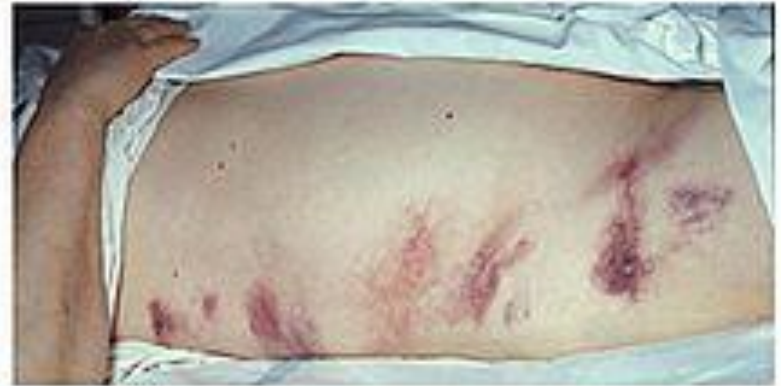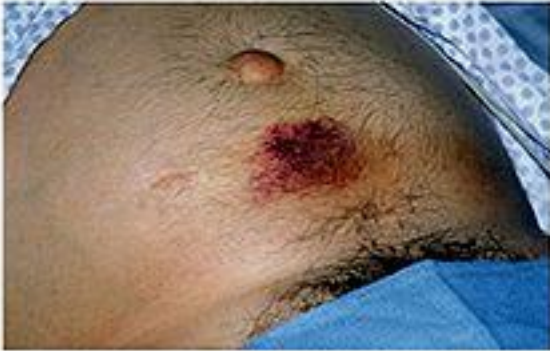Inspection

- ◆ Evaluate **general appearance**:
 - ◆ Renal or biliary colic- **find no comfortable position**
 - ◆ Peritonitis- remain **still in bed**
 - ◆ **Pale or sweating**- shock, pancreatitis or perforated gastric ulcer

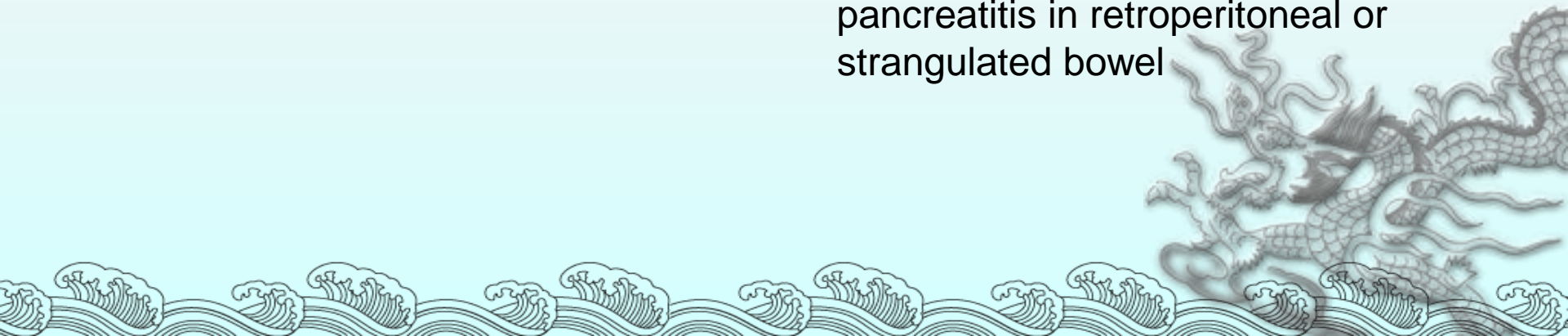


Cullen sign / Grey Turner's sign

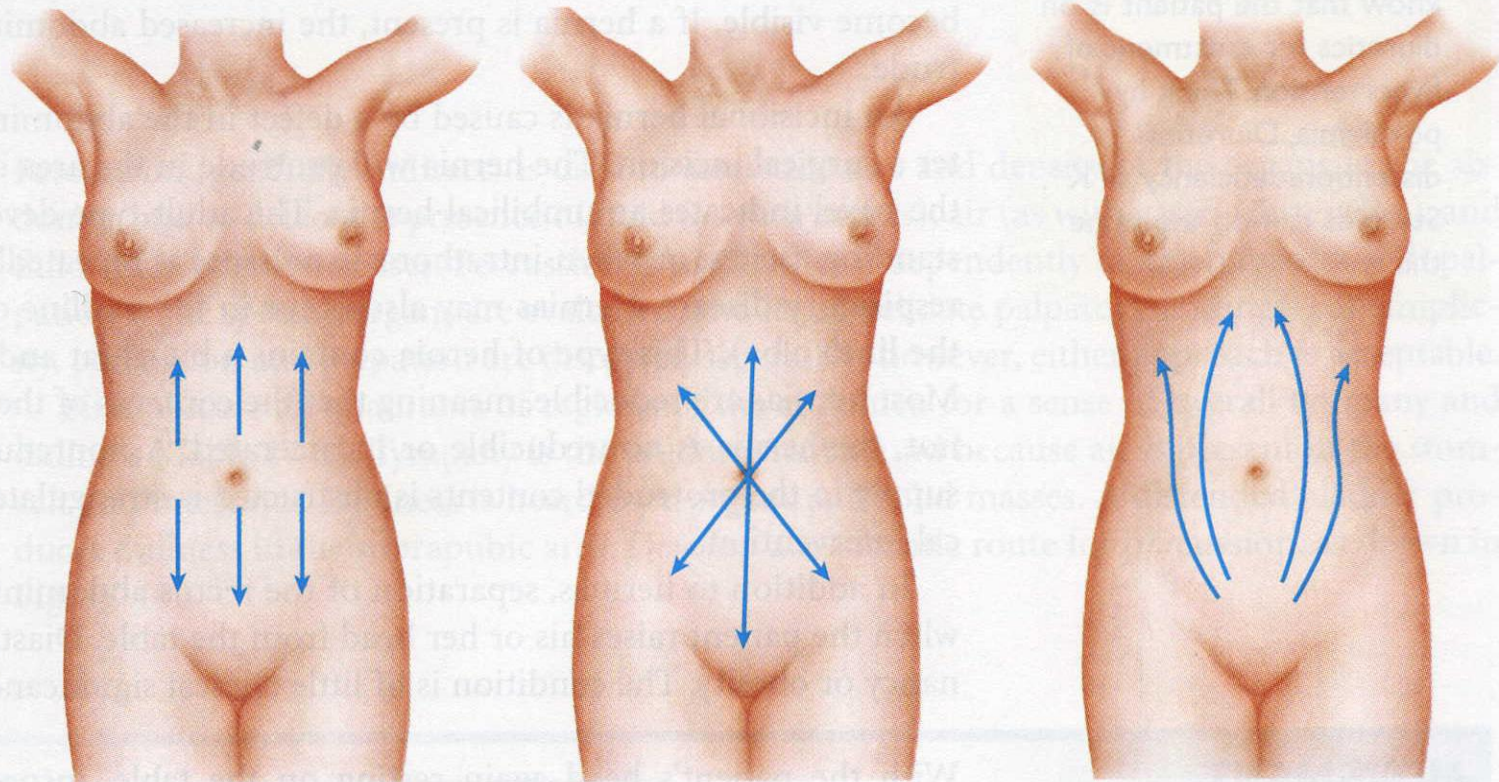
Cullen sign: bruising in the subcutaneous fatty tissue around the umbilicus (ex. Hemorrhagic pancreatitis)



Grey Turner's sign: hemorrhagic pancreatitis in retroperitoneal or strangulated bowel



Direction of venous return



False pregnancy
Fatal tumor

FIGURE 17-7

Abdominal venous patterns.
A, Expected. B, Portal hyper-
tension. C, Inferior vena cava
obstruction.

A

B

C

NP

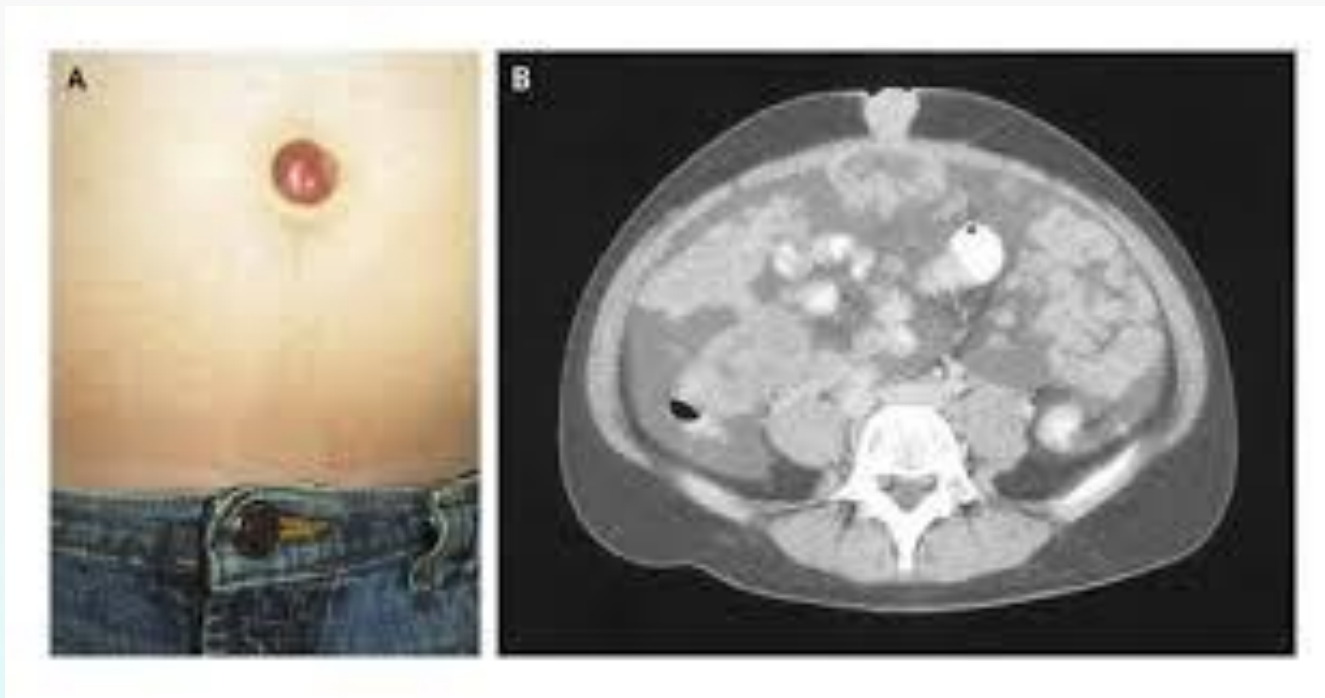
Portal hypertension

IVC obstruction



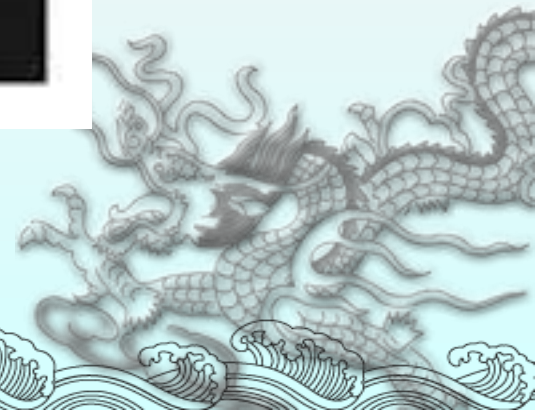
Sister Mary Joseph nodule

- ◆ a palpable nodule bulging into the umbilicus as a result of metastasis of a malignant cancer in the pelvis or abdomen.



Seidel HM, Ball JW, Dains JE, Benedict GW.

Mosby's Guide to Physical Examination, sixth edition (2006). P533-534



Scar and past Hx- the presence of scarring should alert you to the possibility of internal adhesion

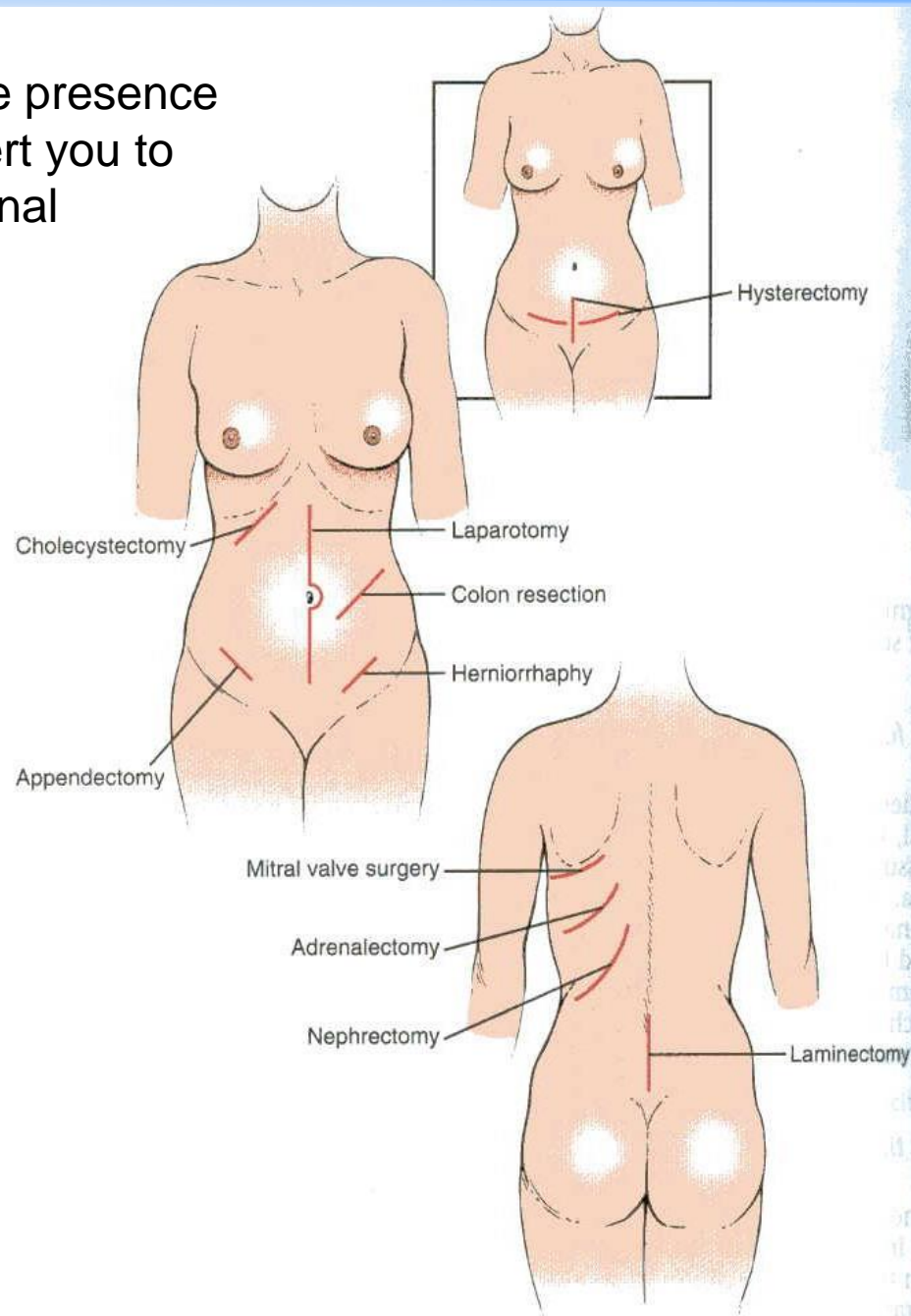


Figure 17-12. Locations of common surgical scars.

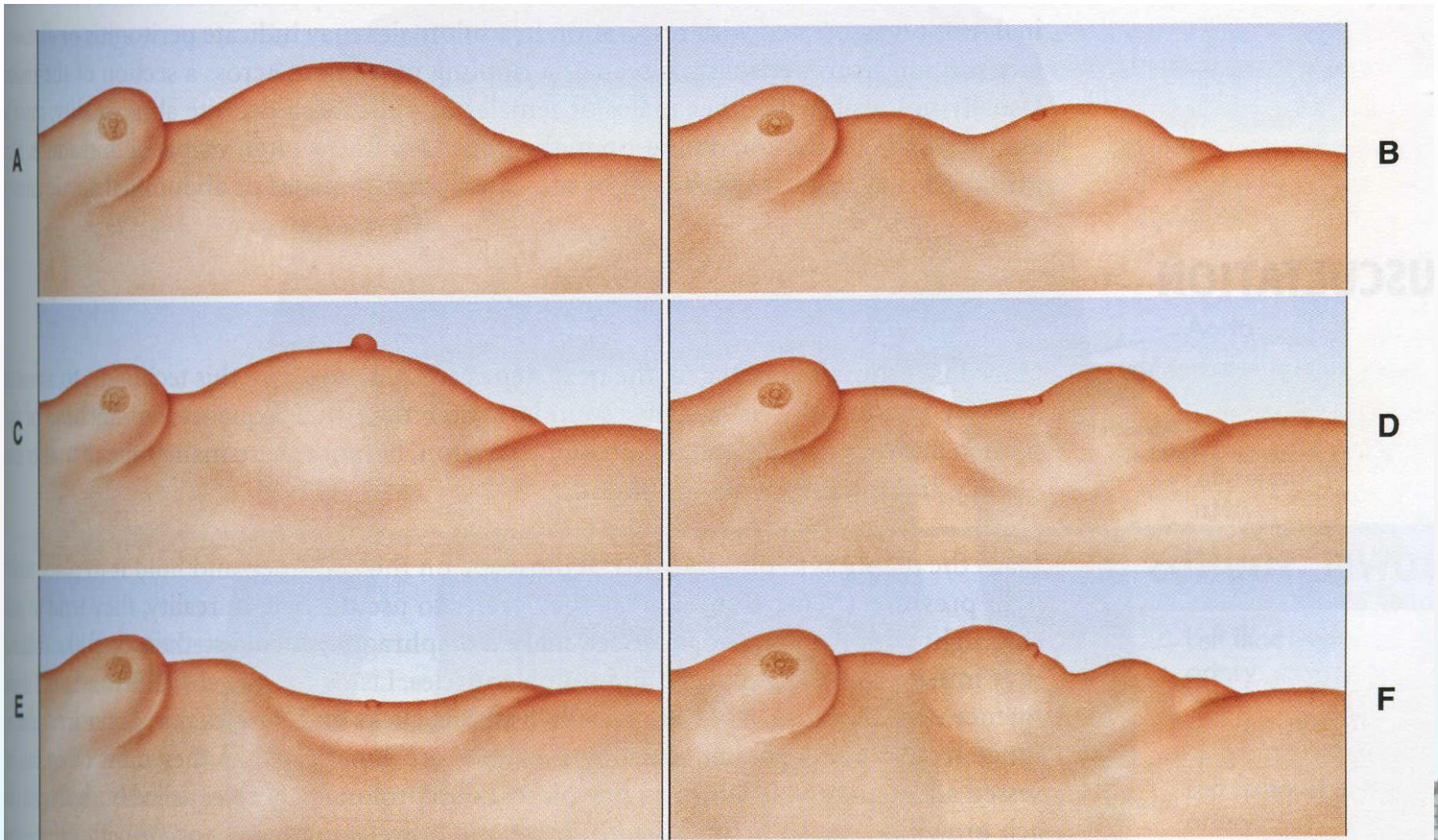



FIGURE 17-8 Abdominal profiles. **A**, Fully rounded or distended, umbilicus inverted. **B**, Distended lower half. **C**, Fully rounded or distended, umbilicus everted. **D**, Distended lower third. **E**, Scaphoid. **F**, Distended upper half.

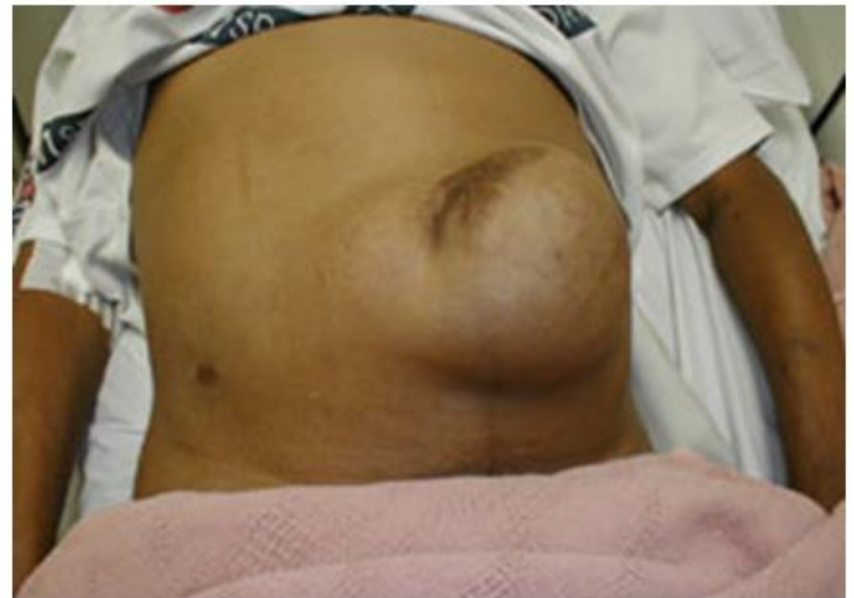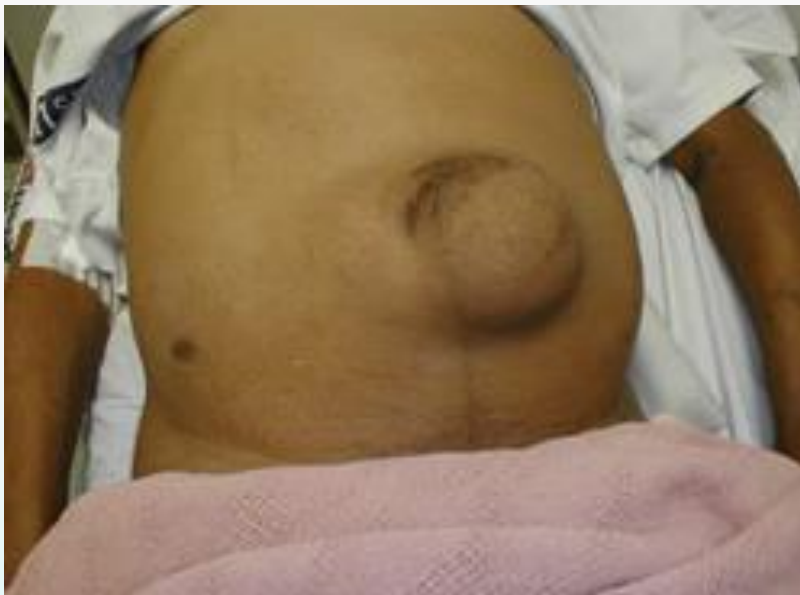Inspection

- ◆ **Distension:**
 - ◆ **B:** From **umbilicus to symphysis**- ovarian tumor, pregnancy, uterine fibroids, or a distended bladder
 - ◆ **F: Upper half:** carcinoma, pancreatic cyst, or gastric dilation
 - ◆ **Asymmetric:** hernia, tumor, cysts, bowel obstruction, or enlargement of abdominal organ



Hernia

Hernia: reducible or nonreducible (incarcerated or even strangulated which requires immediate surgical intervention) in inguinal, umbilical and femoral



To take a deep breath and hold it, to raise his head from the table- contracts the rectus abdominis muscles (superficial abdominal wall mass or hernia may protrude)

Striate: result from pregnancy or weight gain / abdominal tumor or ascites also stretches

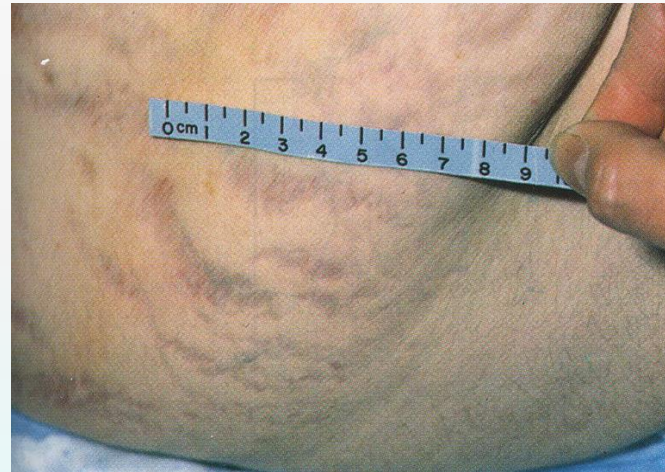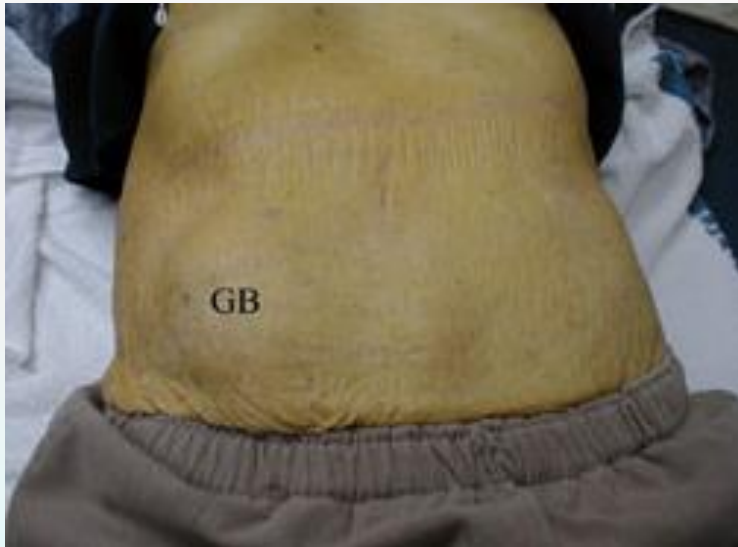
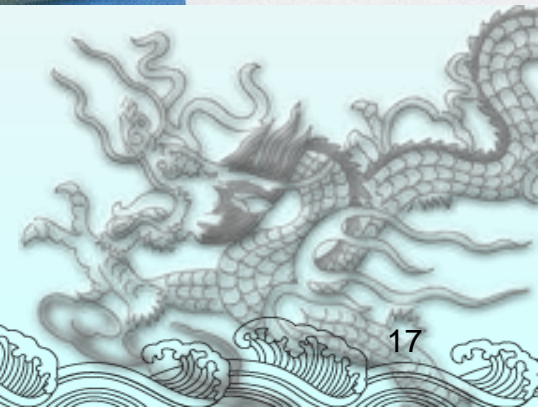


Figure 17-11. Abdominal striae.



Jaundice

鞏膜黃疸 (scleral icterus)：血清膽色素增加超過 $2[\text{mg/dL}]$ 時，皮膚與黏膜就隨之呈現黃色的顏色出來。

Figure 17-5. Jaundice.

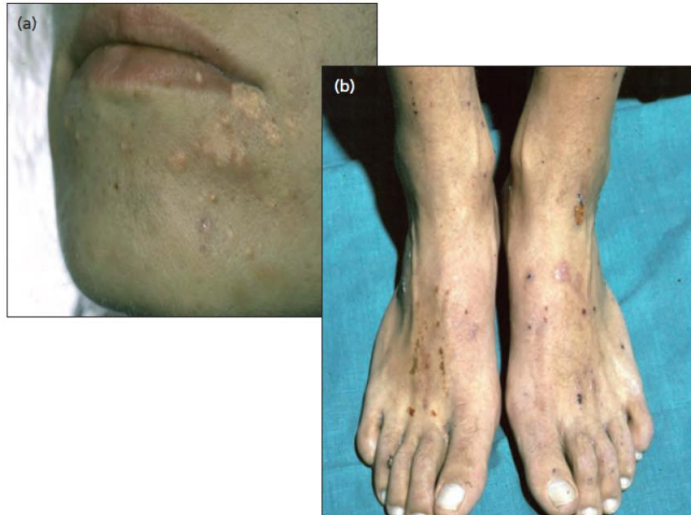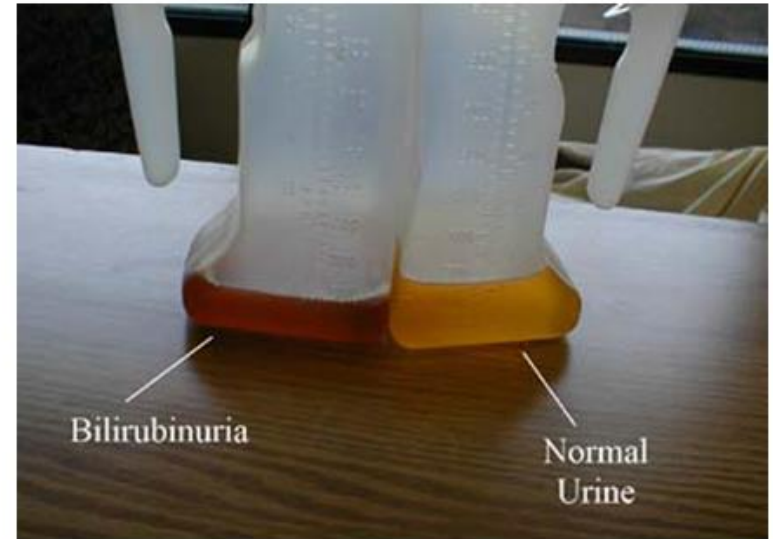

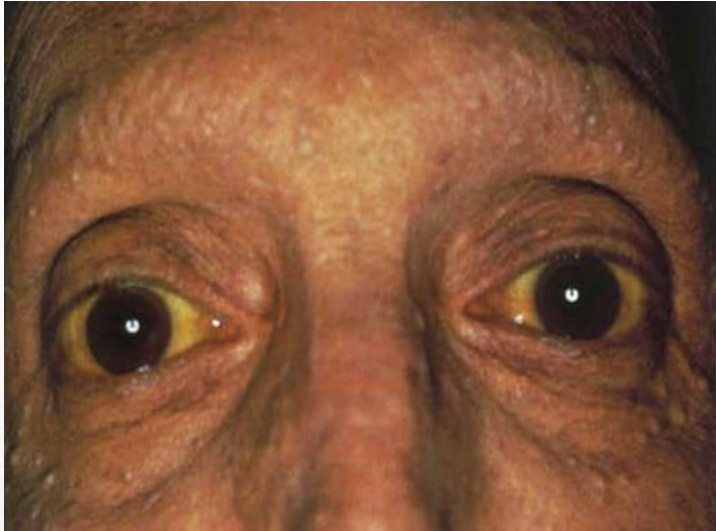
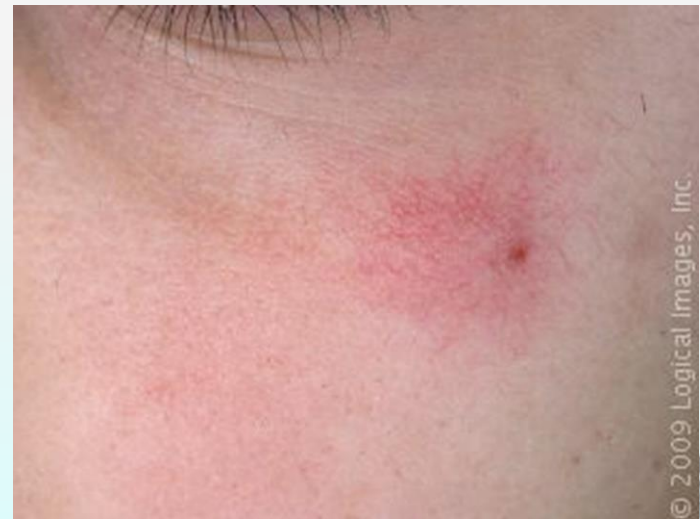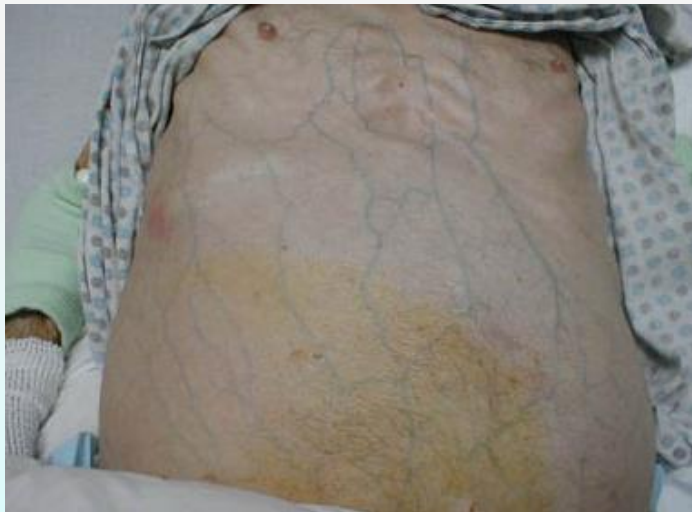Fig. 11.10. A patient with cholestatic jaundice who demonstrates the classical features of (a) cutaneous cholesterol deposits and (b) scratch marks in response to pruritus.

Spider angioma

(LC or pregnancy, collagen vascular disorders)

Ascites: glistening, taut appearance

蜘蛛樣血管瘤（spider angioma，多見於前胸上部、頸部或臉部）：肝硬化病人因為性荷爾蒙代謝的改變，而容易在前胸軀幹部形成許多由小血管環繞中央小動脈的蜘蛛痣。蜘蛛痣的大小和數量，在某種程度上和肝硬化嚴重度成正比。



Liver cirrhosis ?

男性女乳 (gynecomastia)：約有三分之二肝硬化的病人會有男性女乳症，這也和肝硬化病人體內異常的性激素代謝相關；造成良性的男性乳腺組織增生。

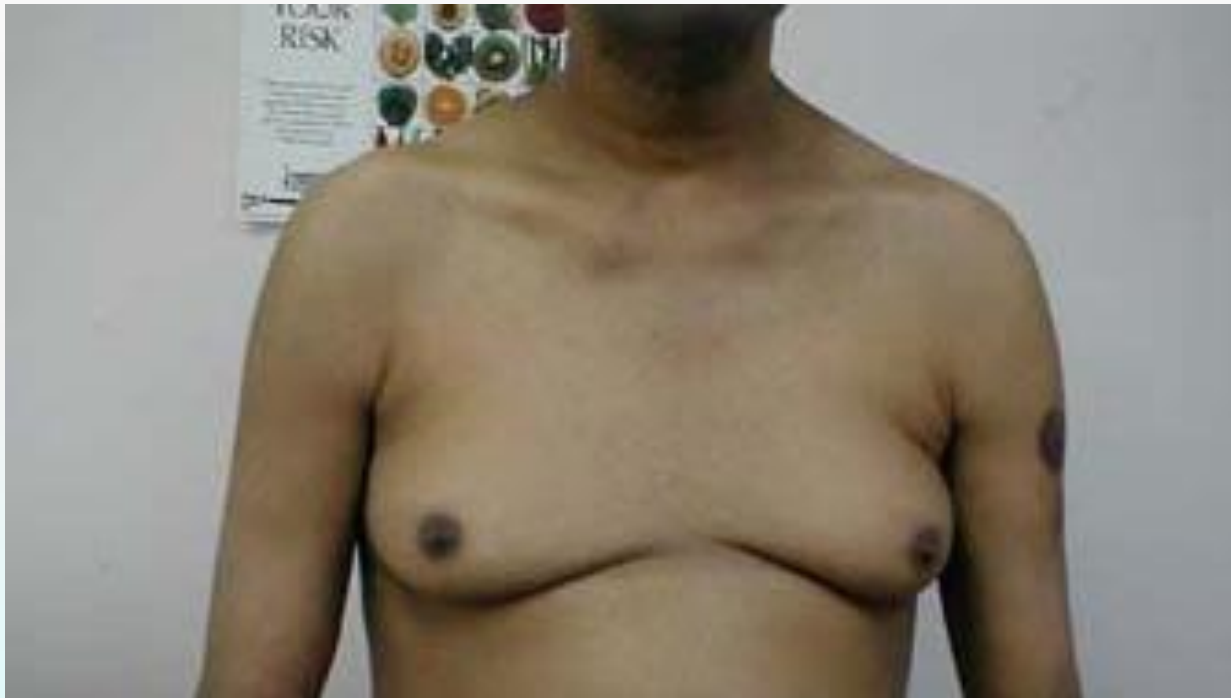

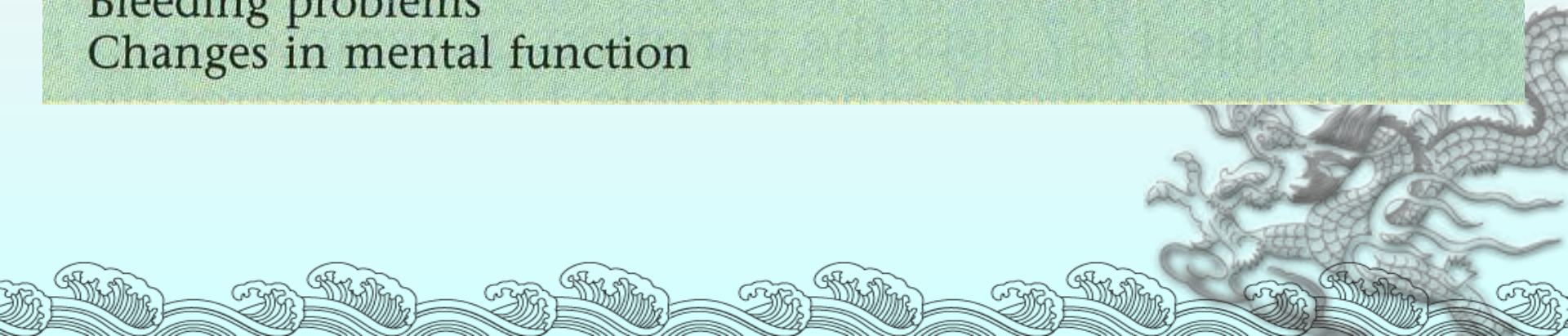TABLE 17–8. Signs and Symptoms of Cirrhosis

Hepatocellular Failure

Spider angiomata
Gynecomastia
Palmar erythema
Ascites
Jaundice
Testicular atrophy
Erectile dysfunction
Bleeding problems
Changes in mental function


Portal Hypertension

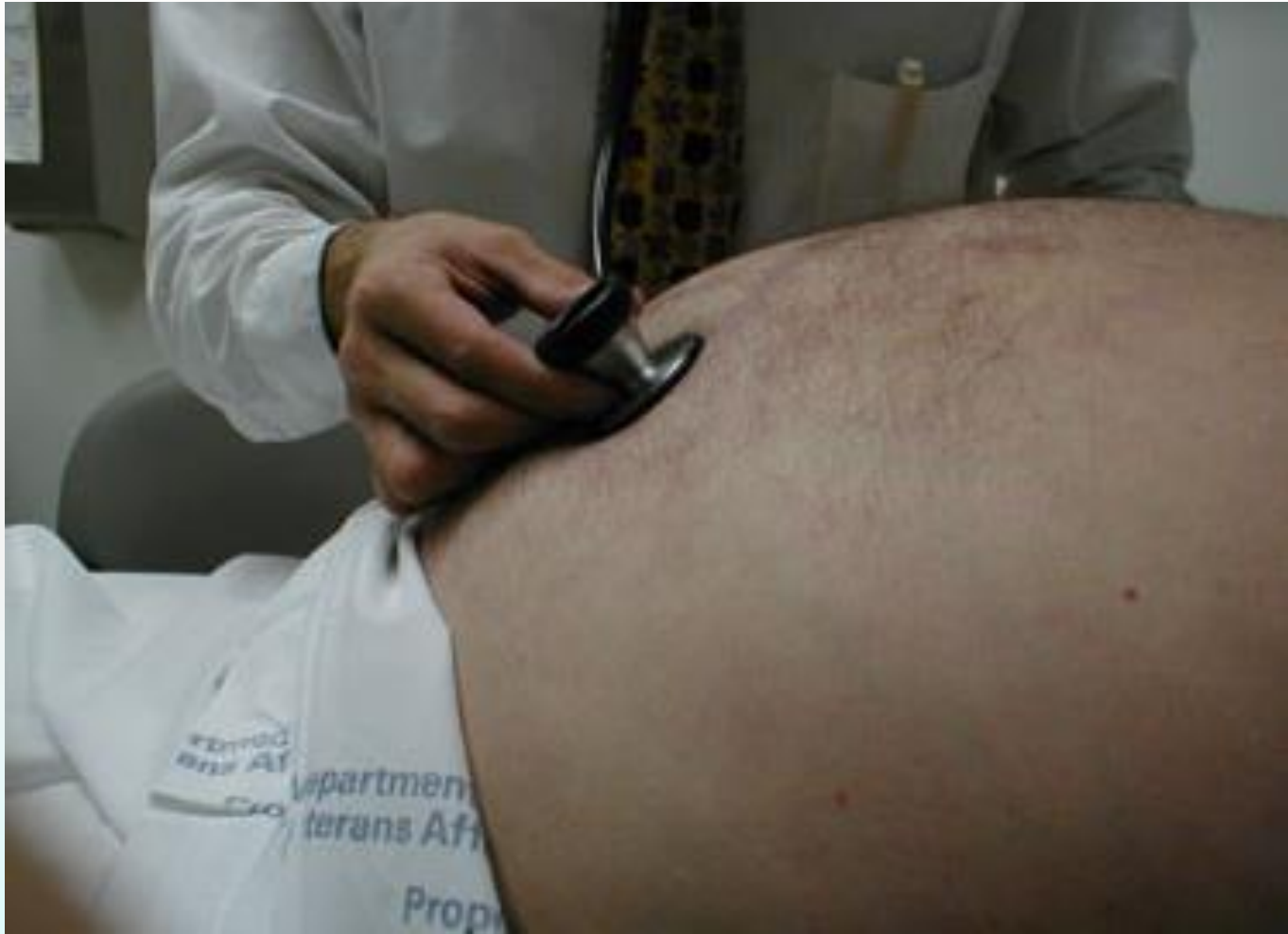
Ascites
Varices: esophageal
Hemorrhoids
Caput medusae
Splenomegaly



腹部身體診察

- ◆ Anatomy
- ◆ Techniques of Examination
 - ◆ General Approach
 - ◆ Inspection
 - ◆ **Auscultation**
 - ◆ Percussion
 - ◆ Palpation
- ◆ Special Maneuver





Auscultation

Bowel sound

- ◆ Auscultation should be performed **before percussion / palpation** with warmed stethoscope.
- ◆ Clicks and gurgles, range from **5-35 per minutes** (any place or four quadrants).
- ◆ **High-pitched** tingling sound: intestinal fluid and air under pressure- as in **early obstruction**.
- ◆ **Decreased** bowel sound: **peritonitis and paralytic ileus**.
- ◆ **Absence** of bowel sound is established only after **2-5** minutes of continuous listening.
- ◆ Succus splash- rule out obstructed viscus.

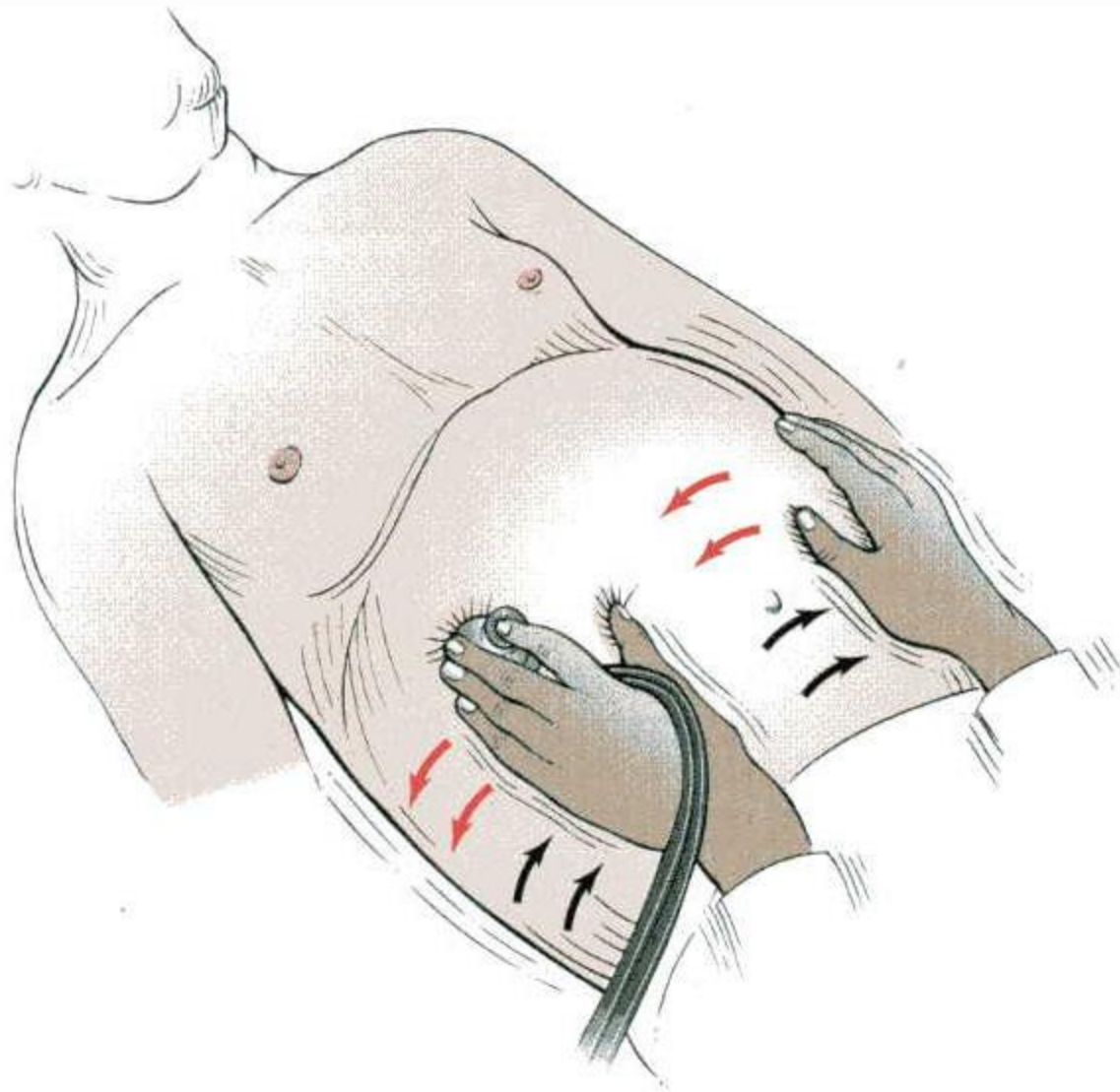



Figure 17-16. “Succussion splash” technique for assessing distention of abdominal viscera.

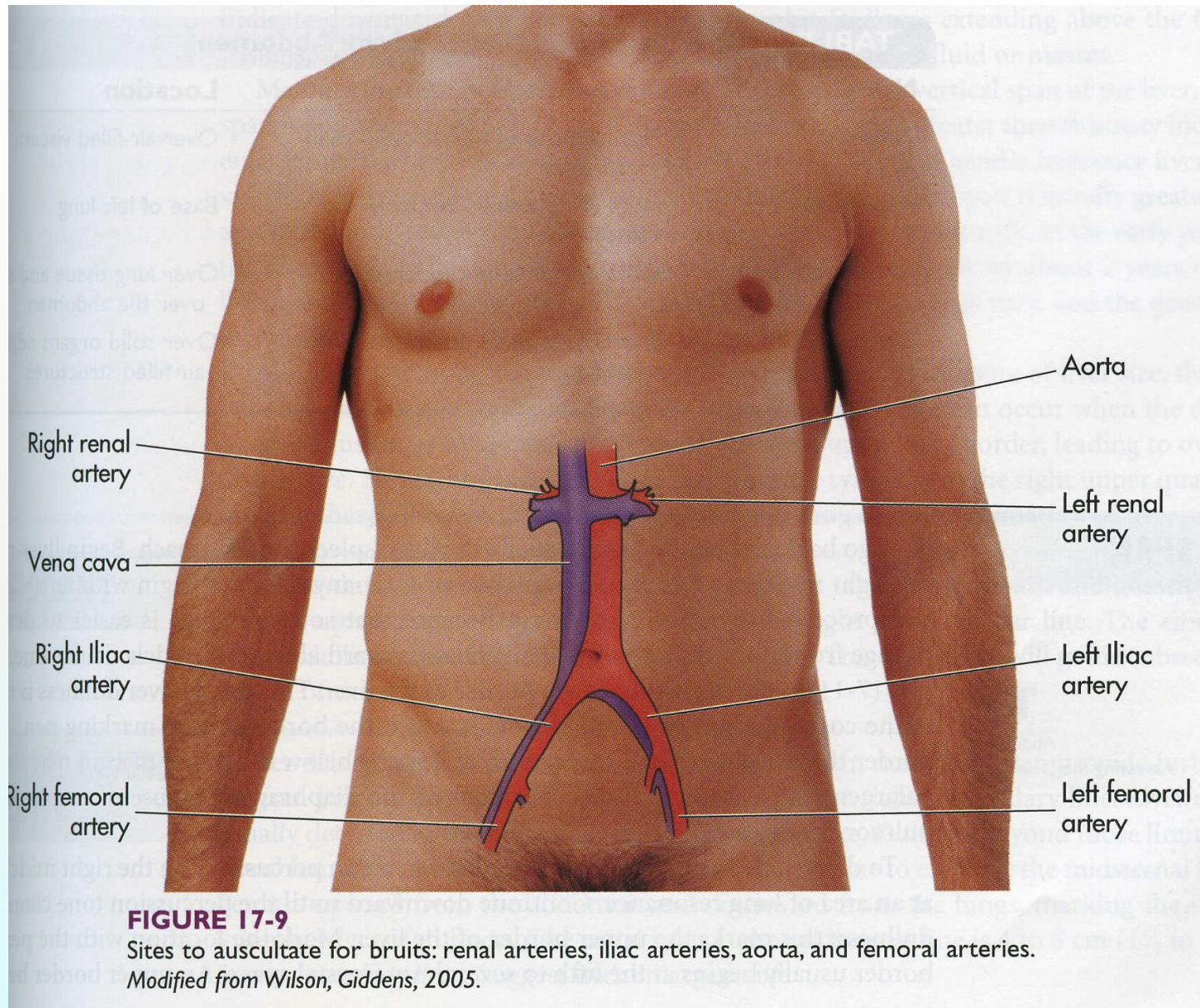


Auscultation

Vascular sound

- ◆ **Bell/diaphragm** for vascular sound.
- ◆ **Bruits (bell)** in the aortic, renal, iliac, and femoral arteries.
- ◆ **Friction rubs** (diaphragm- high pitched and association with respiration) over liver and spleen: **tumor**, infection, or infarct.
- ◆ **Venous hum** (soft, low pitched, and continuous): increased **collateral circulation** between portal systemic and systemic venous systems.





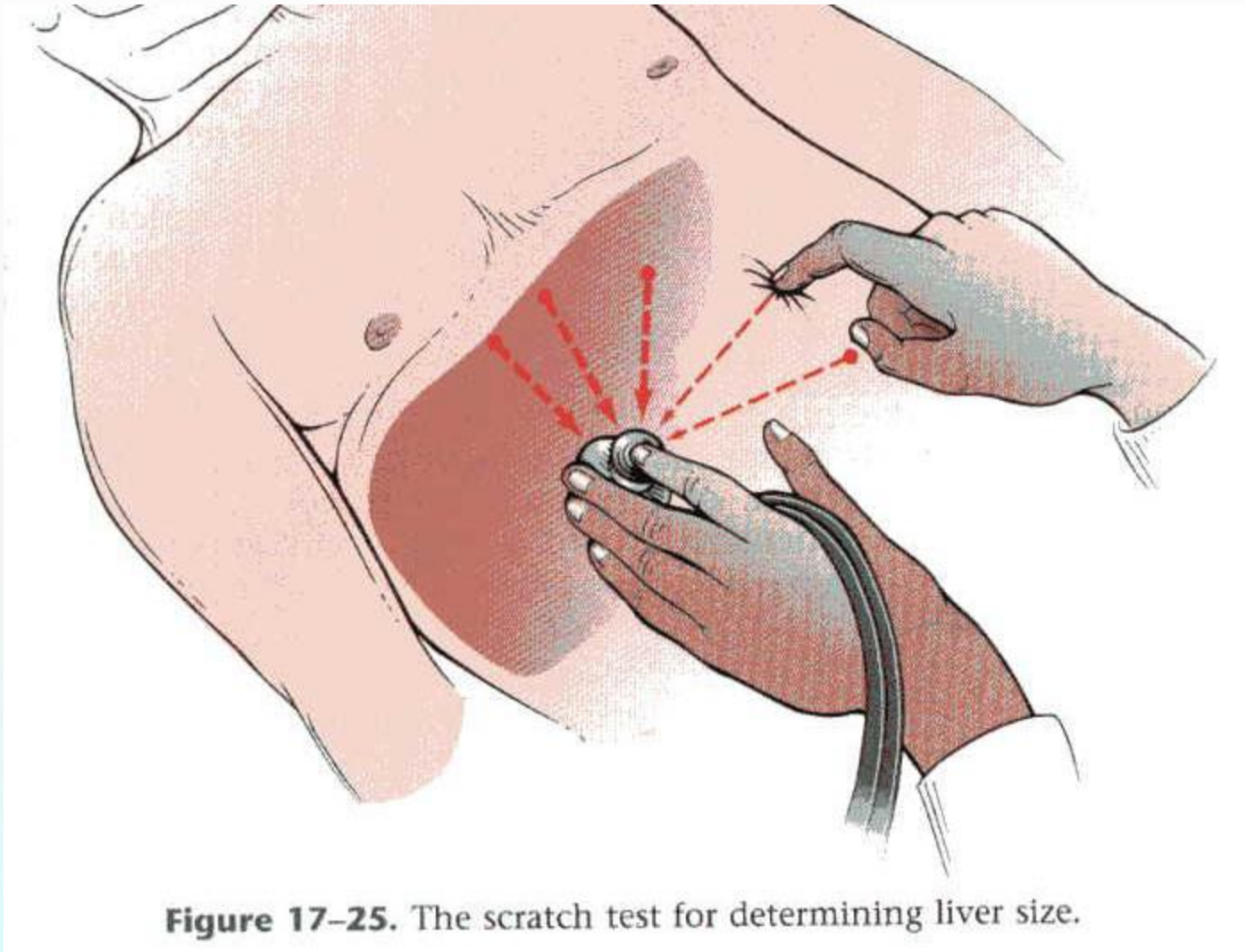
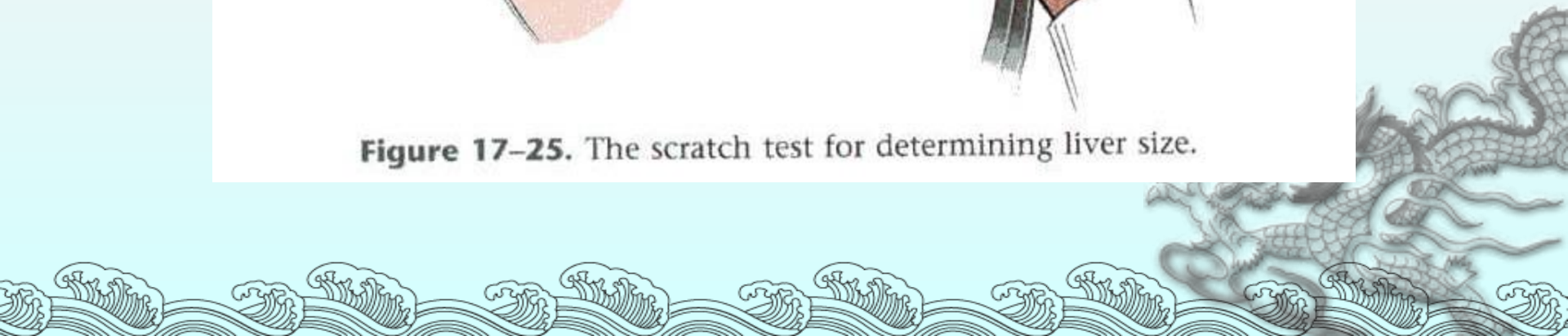



Figure 17-25. The scratch test for determining liver size.




腹部身體診察

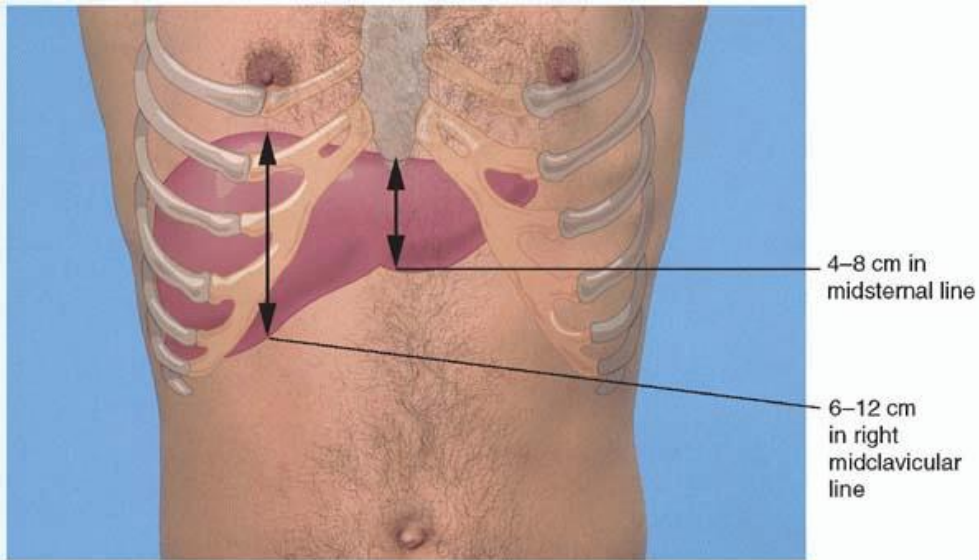
- ◆ Anatomy and Physiology
- ◆ Techniques of Examination
 - ◆ General Approach
 - ◆ Inspection
 - ◆ Auscultation
 - ◆ Percussion
 - ◆ Palpation
- ◆ Special Maneuver



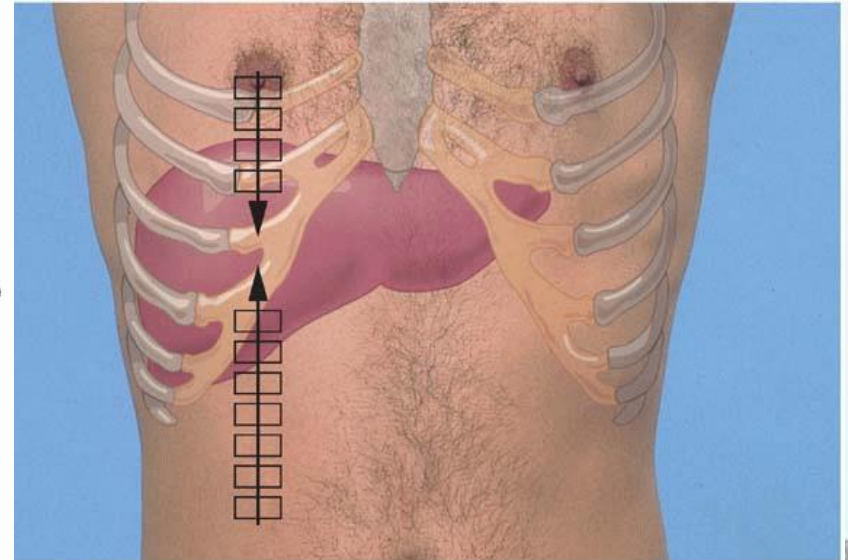
Percussion

- ◆ Percussion is used either independently or concurrently with palpation
- ◆ Tympany- is the predominant sound because air is present in the stomach and intestine.
- ◆ Hyperresonance- pitch lies between tympany and resonance
- ◆ Resonance- sustained note of moderate pitch
- ◆ Dullness- is heard over organs and solid masses.







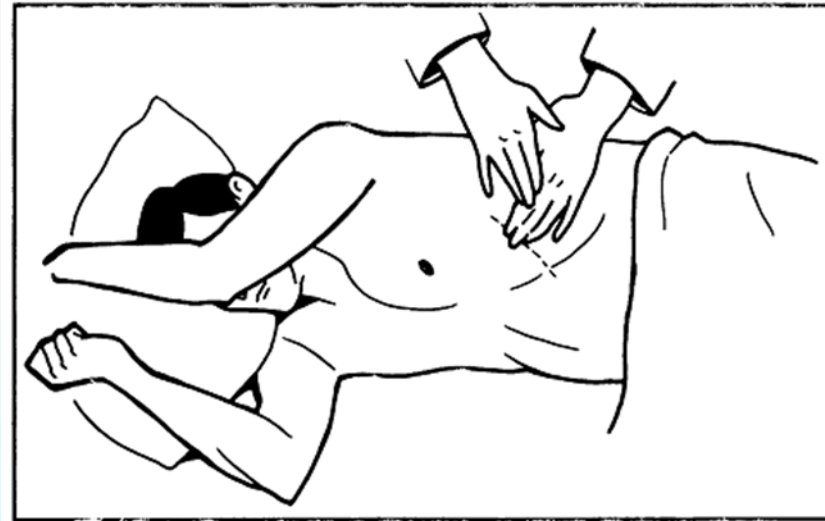
NORMAL LIVER SPANS



PERCUSSING LIVER SPAN




扣診脾臟：病人右側躺，由後腋線(posterior axillary line)和肋骨下緣交叉點垂直肋骨下緣往上敲，濁音正常範圍為肋骨上緣6-8公分，若超過8公分仍有濁音懷疑為脾腫大。



腹部身體診察


- ◆ Anatomy and Physiology
- ◆ Techniques of Examination
 - ◆ General Approach
 - ◆ Inspection
 - ◆ Auscultation
 - ◆ Percussion
 - ◆ **Palpation**
- ◆ Special Maneuver



Palpation


- ◆ Light palpation
- ◆ Moderate palpation
- ◆ Deep palpation

- ◆ Masses
- ◆ Umbilical ring
- ◆ Bimanual technique

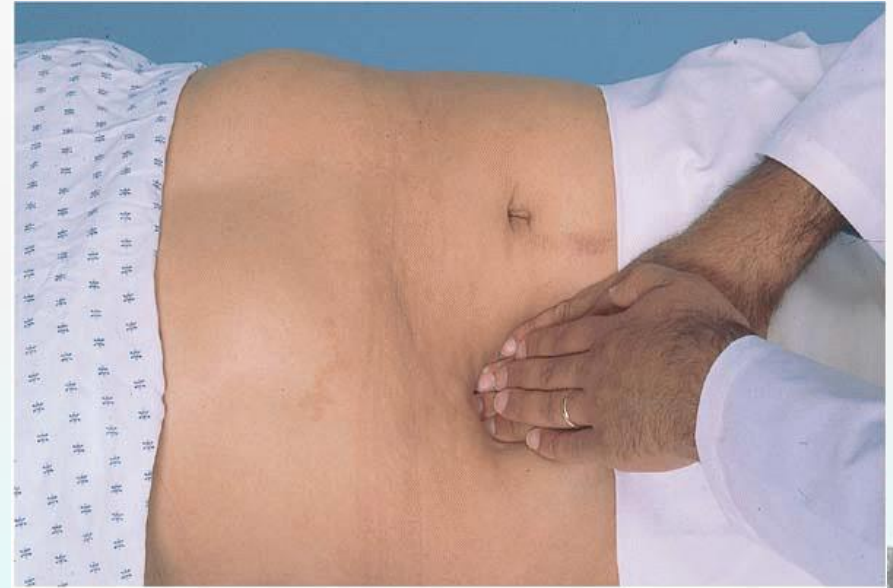
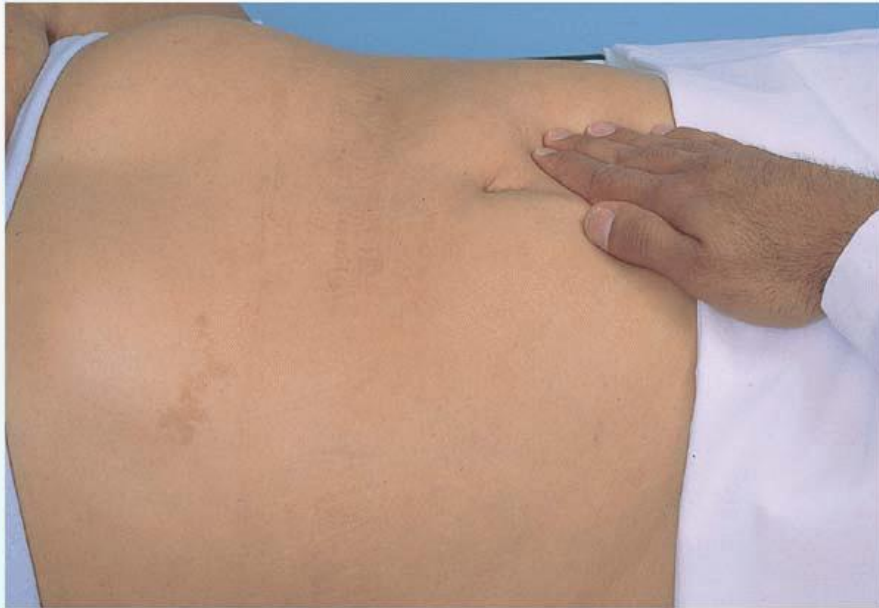
Palpation

- ◆ Light palpation (single hand) & Deep palpation (two hand)
- ◆ Liver: soft, sharp, smooth and regular surface.
(hooking method sometimes)
- ◆ Spleen: difficult in normal condition.
(supine or lying on right side)
- ◆ Kidney: mild difficult in normal left kidney.
- ◆ Aorta



Light Palpation and Deep Palpation



TWO-HANDED DEEP PALPATION



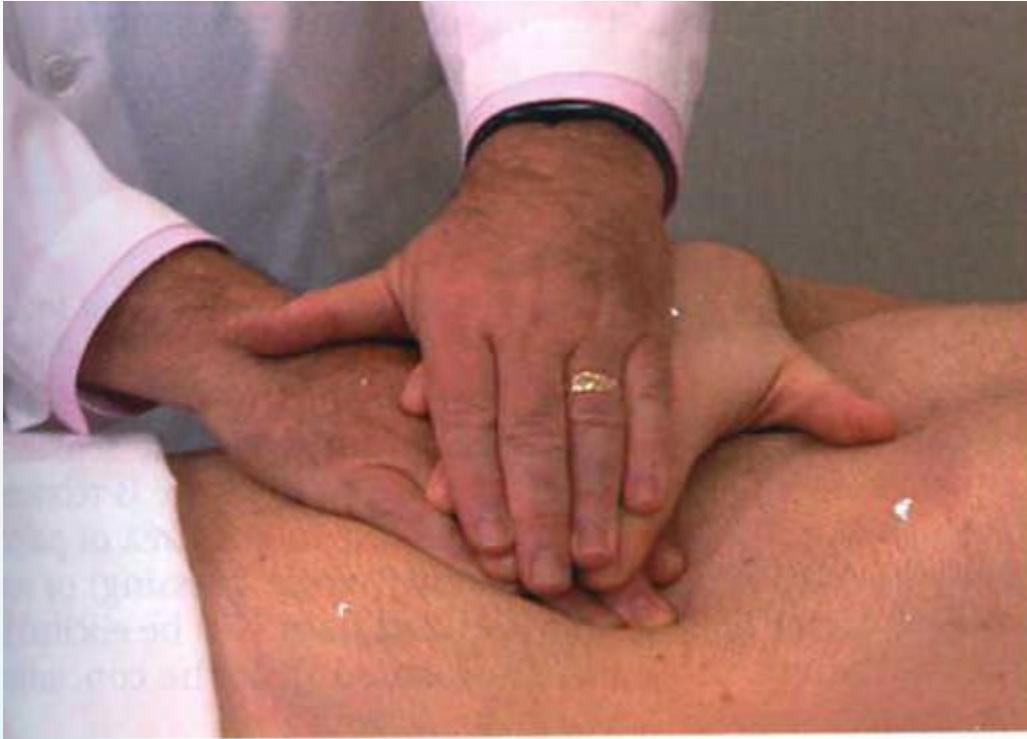



Figure 17-21. Technique used for ticklish patients. The patient's hand is sandwiched between the examiner's hands.



Kidney

Fecal mass
(cecum)

Uterus
(gravid)

Aorta

Sacral
promontory

Fecal mass
(sigmoid)

Bladder

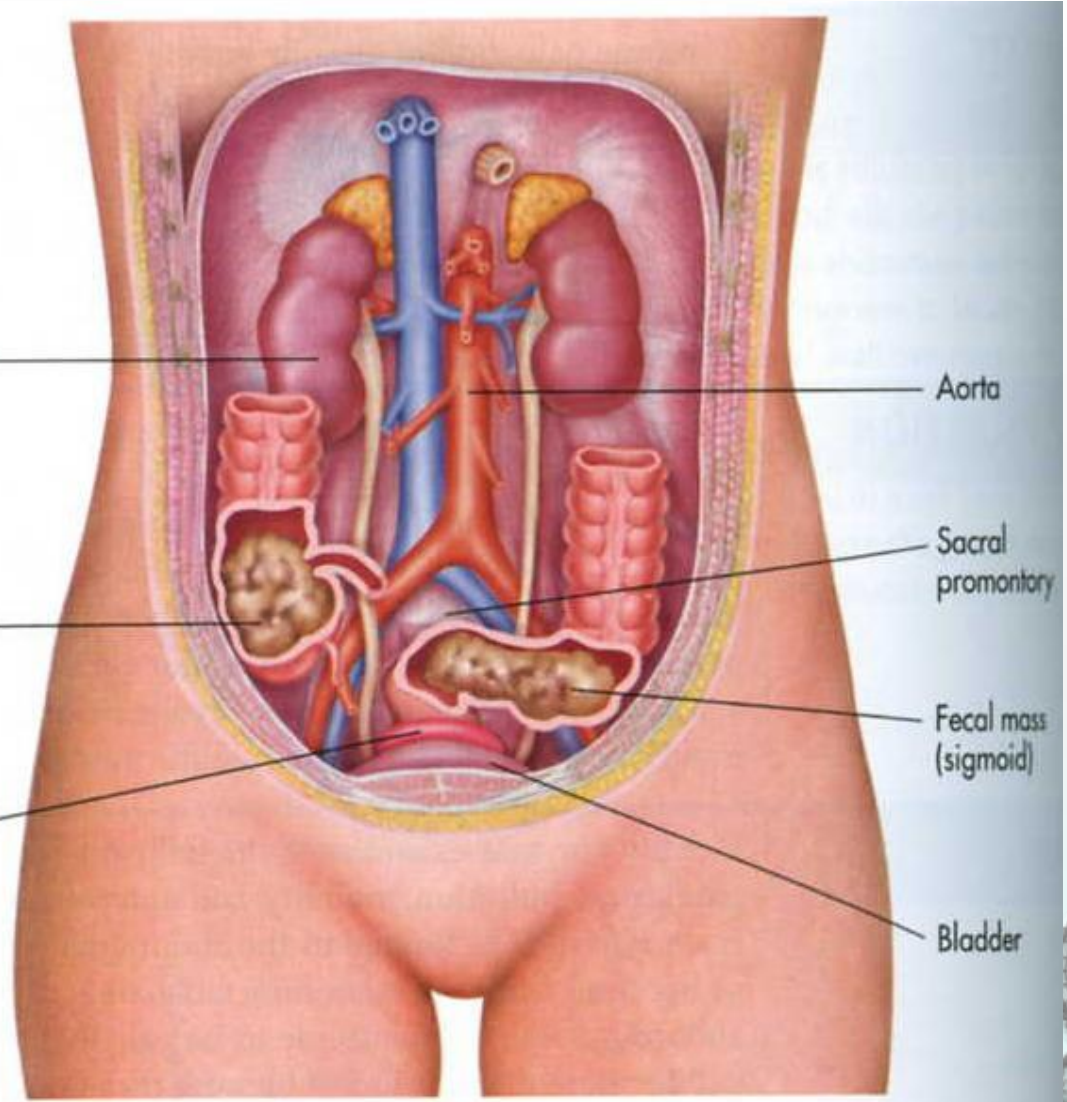
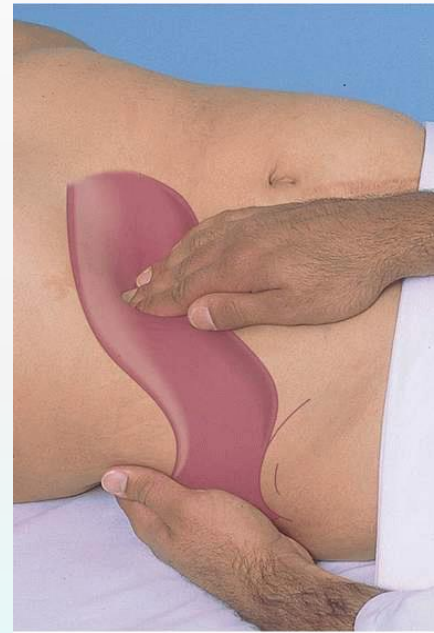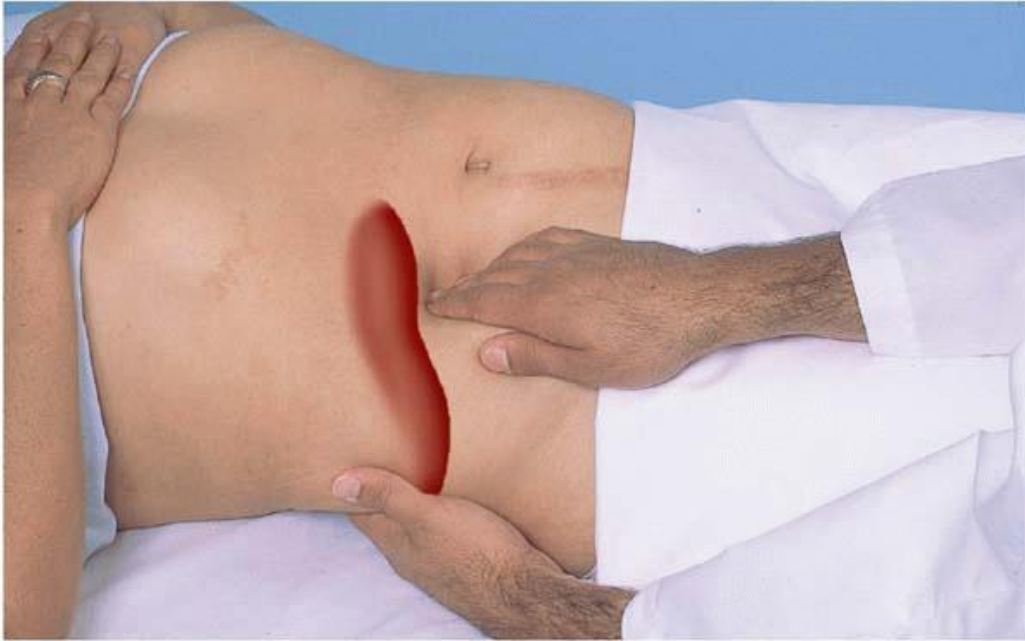


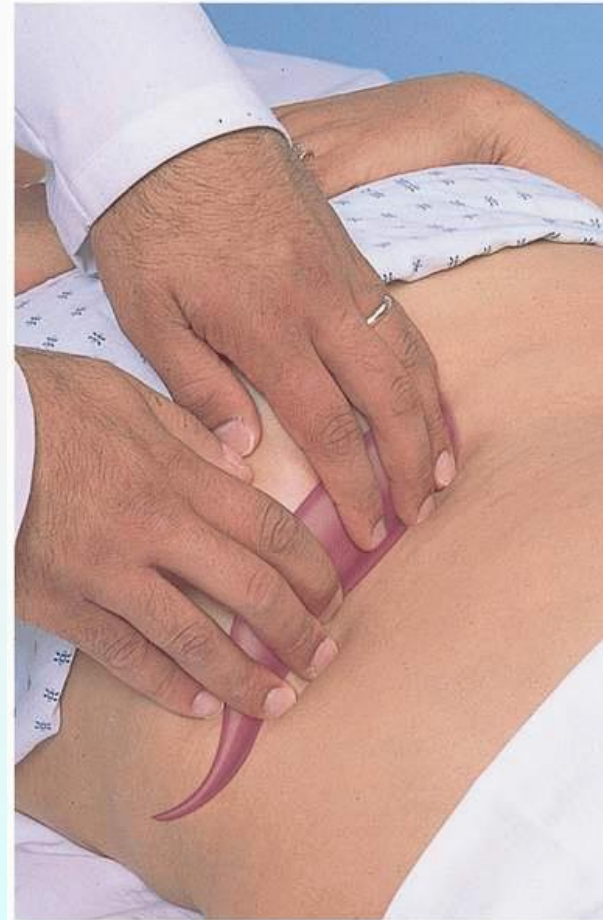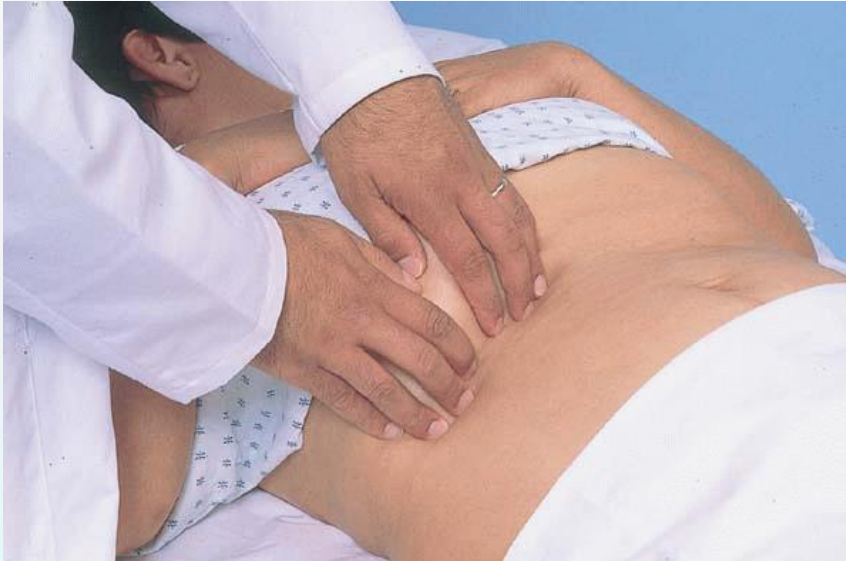FIGURE 17-19

Abdominal structures commonly
felt as masses.

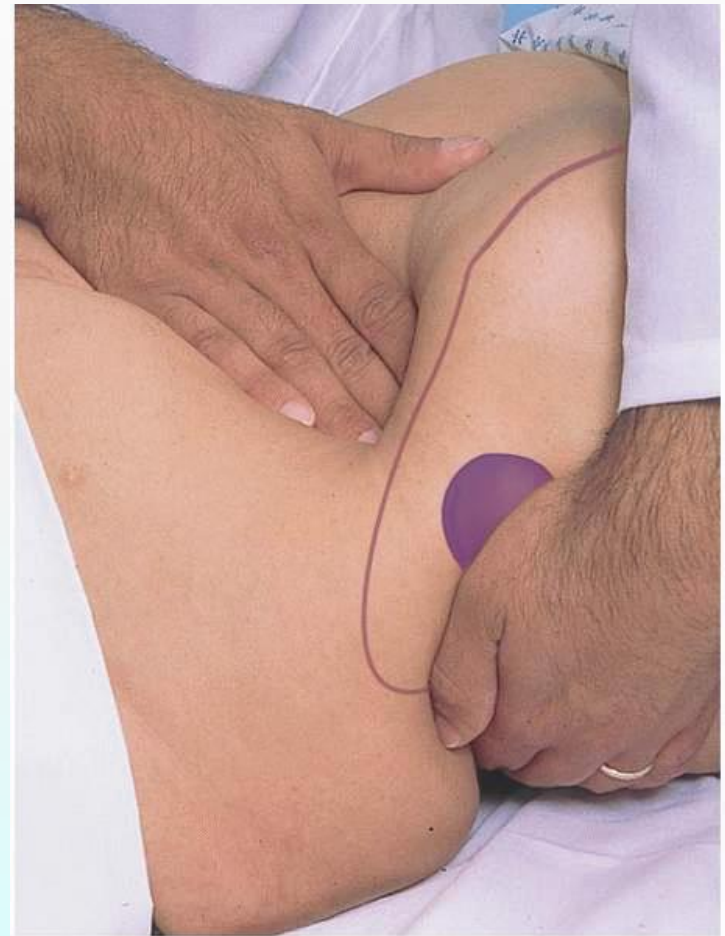
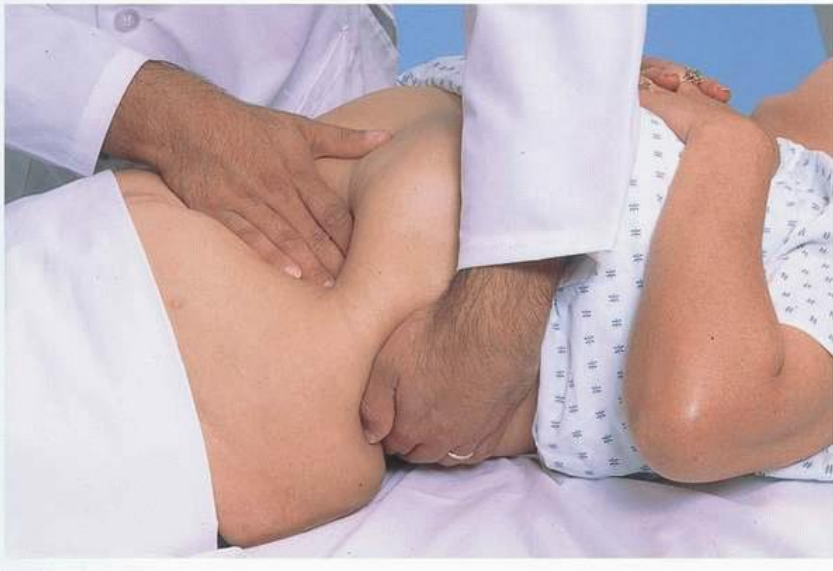Feel the liver



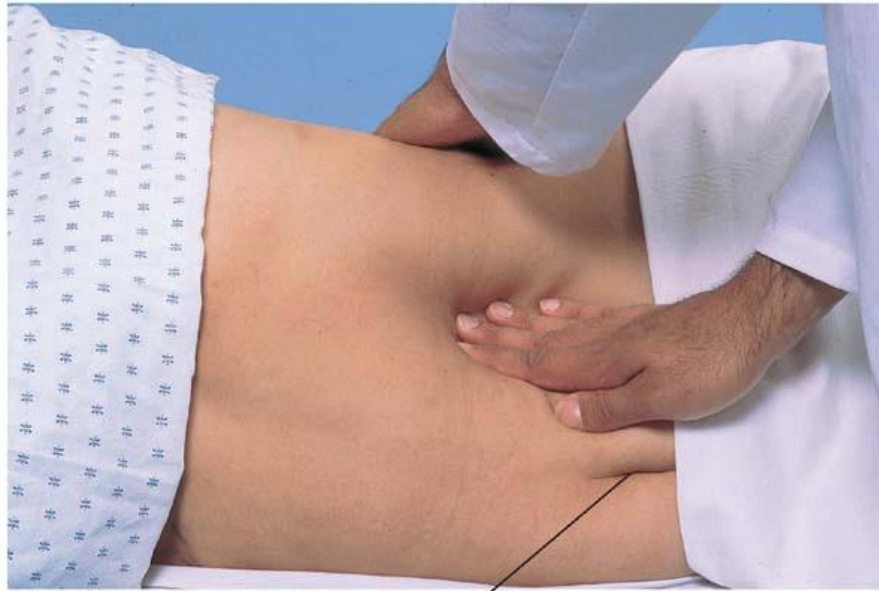Hooking technique



Feel the spleen

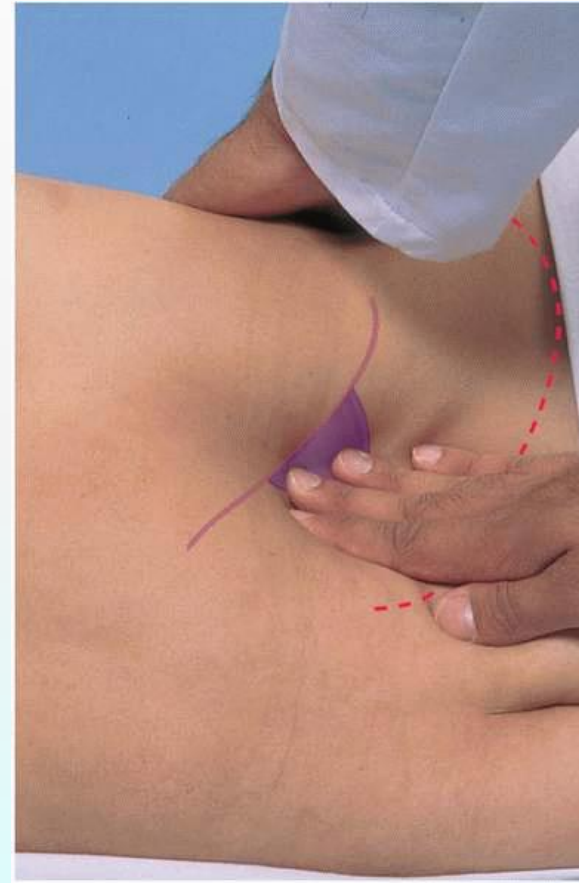


Feel the spleen

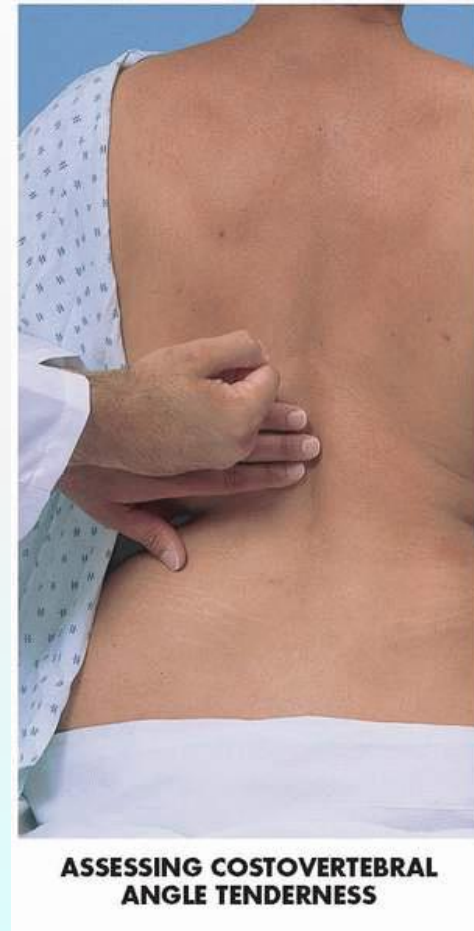
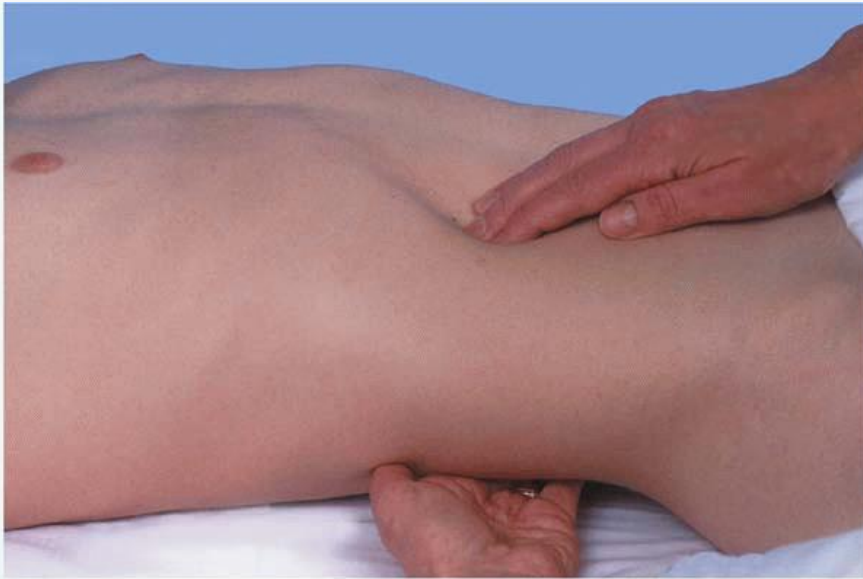
Umbilicus

PALPATING THE SPLEEN—PATIENT LYING ON RIGHT SIDE




Assessing Percussion Tenderness of the Kidneys



腹部身體診察


- ◇ Anatomy
- ◇ Techniques of Examination
 - ◇ General Approach
 - ◇ Inspection
 - ◇ Auscultation
 - ◇ Percussion
 - ◇ Palpation
- ◇ **Special Maneuver**



Additional procedures

Pain assessment

- ◆ Assessment for **peritoneal irritation**
 - ◆ Ask the patients to cough, then identified the tender point
 - ◆ Palpate gently with one finger by patient, look for **rebound tenderness** or **muscle guarding**
(False Negative in Elder, DM, Immunocompromised, Sedative or Control pain by medication)



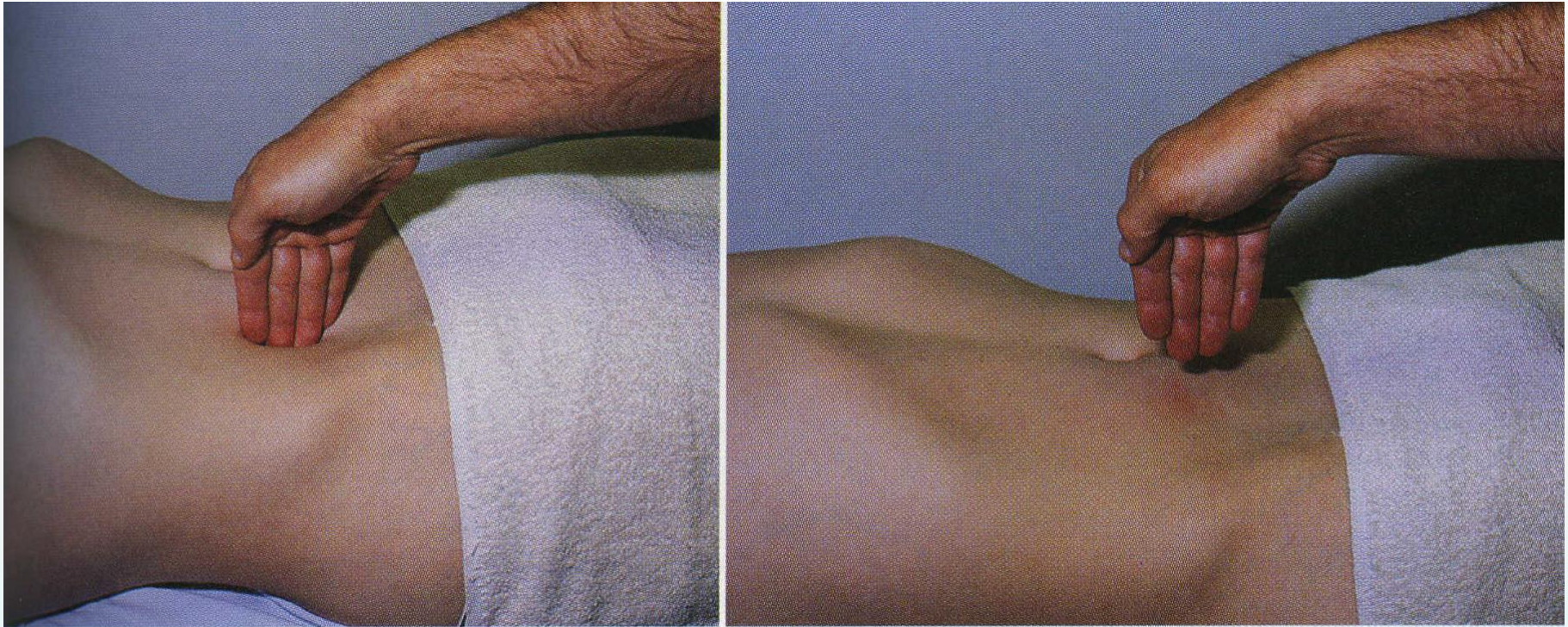


FIGURE 17-33

Testing for rebound tenderness. **A**, Press deeply and gently into the abdomen. **B**, Then rapidly withdraw the hands and fingers.


TABLE 17-4**Quality and Onset of Abdominal Pain**

Characteristic	Possible Related Condition
Burning	Peptic ulcer
Cramping	Biliary colic, gastroenteritis
Colic	Appendicitis with impacted feces; renal stone
Aching	Appendiceal irritation
Knifelike	Pancreatitis
Ripping, tearing	Aortic dissection
Gradual onset	Infection
Sudden onset	Duodenal ulcer, acute pancreatitis, obstruction, perforation




TABLE 17-3. Maneuvers for Ameliorating Abdominal Pain

Maneuver	Affected Organ	Clinical Example
Belching	Stomach	Gastric distention
Eating	Stomach, duodenum	Peptic ulcer
Vomiting	Stomach, duodenum	Pyloric obstruction
Leaning forward	Retroperitoneal structures	Pancreatic cancer, Pancreatitis
Flexion of knees	Peritoneum	Peritonitis
Flexion of right thigh	Right psoas muscle	Appendicitis
Flexion of left thigh	Left psoas muscle	Diverticulitis



Additional procedures

- ◆ Ascites assessment
 - ◆ **Shifting dullness**
 - ◆ Fluid wave
 - ◆ Auscultatory percussion
 - ◆ Puddle sign

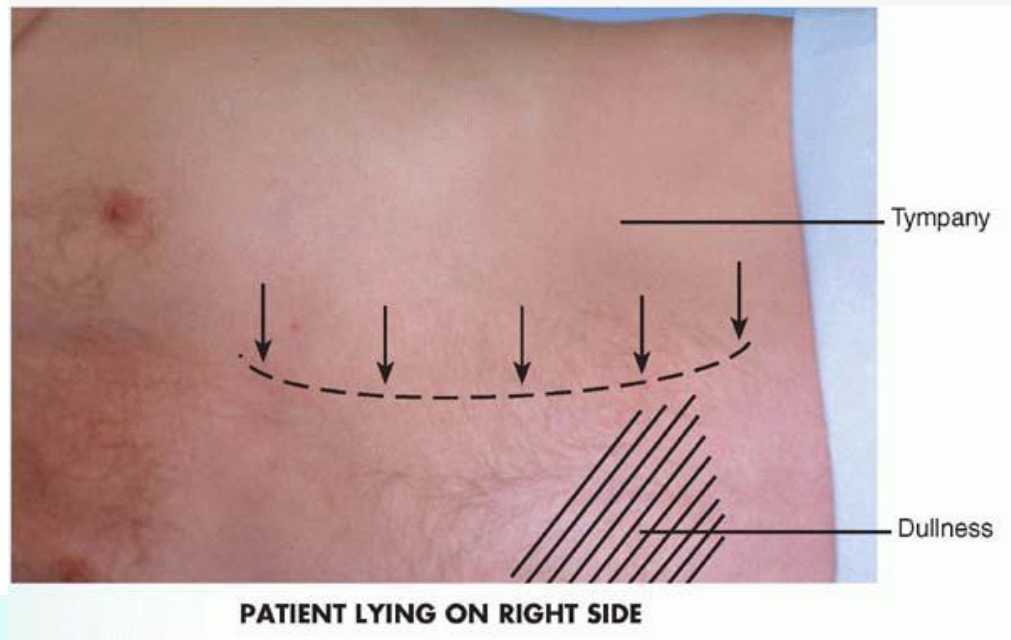
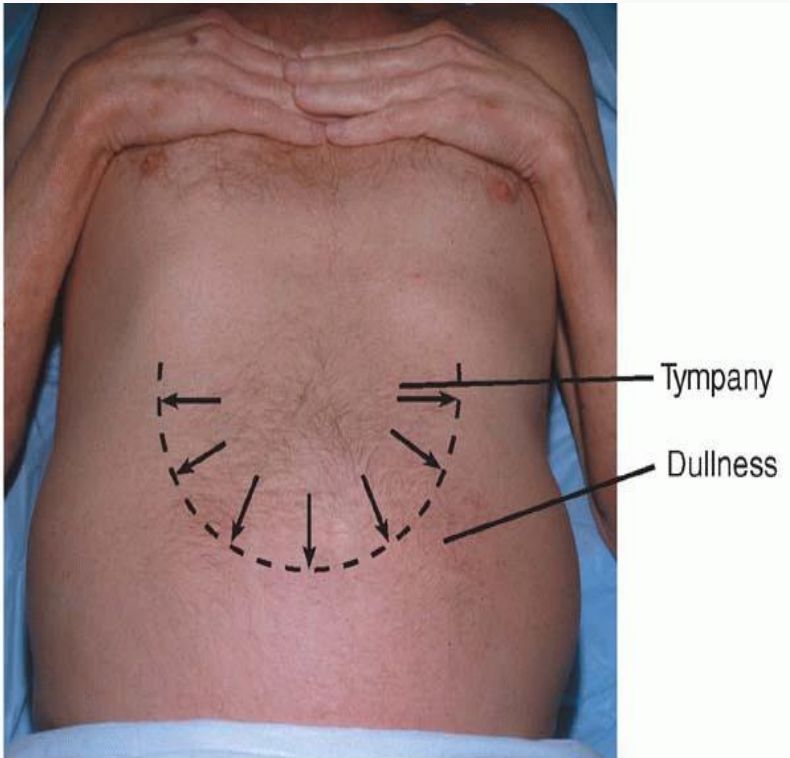


Shifting dullness

- ◆ This is a test for peritoneal fluid ([ascites](#)).
- ◆ Percuss the patient's abdomen to outline areas of dullness and tympany.
- ◆ Have the patient roll away from you.
- ◆ Percuss and again outline areas of dullness and tympany.
- ◆ If the dullness has shifted to areas of prior tympany, the patient may have excess peritoneal fluid



Outline areas of dullness



Test for a fluid wave and shifting dullness

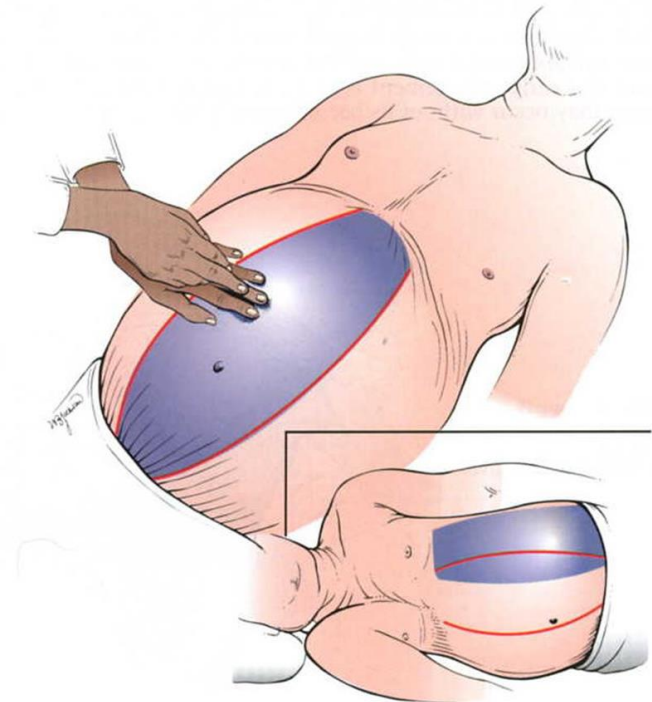
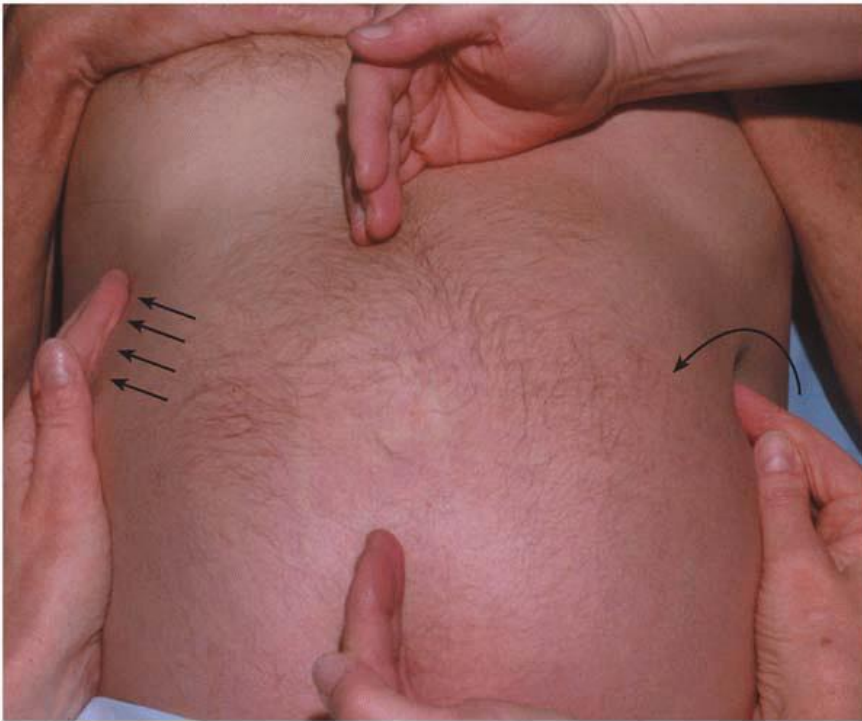


Figure 17-18. Technique for testing for shifting dullness. The colored areas represent the areas of tympany.

TABLE 17-4. Characteristics of Physical Signs (Pooled Data) for Detection of Ascites*

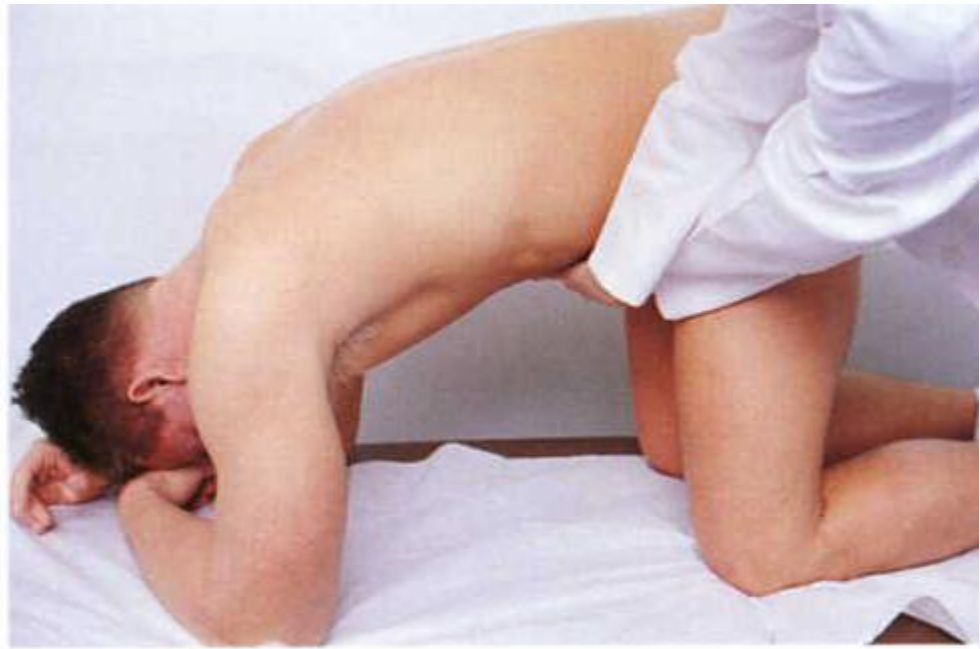Physical Sign	Sensitivity (%) and Range	Specificity (%) and Range	LR+	LR-
Bulging flanks	81 69-93	59 50-68	2.0	0.3
Flank dullness	84 80-94	59 47-71	2.0	0.3
Shifting dullness	86 64-90	72 63-81	2.7	0.3
Prominent fluid wave	62 47-77	90 84-96	6.0	0.4

*95% confidence interval; data pooled from Cummings et al (1985), Simel et al (1988), Cattau et al (1982), and Williams and Simel (1992).




FIGURE 17-32

Testing for pooling abdominal fluid. Percuss the umbilical area for dullness.



Appendicitis

- ◆ Migration pain from upper, **periumbilical** to **RLQ** **rebounding pain** or muscular rigidity.
- ◆ **Rovsing's sign** : RLQ pain when palpation LLQ
- ◆ **Psoas sign**
- ◆ **Obturator sign**
- ◆ **Rectal examination** or pelvic examination for DDx **PID** and other disease

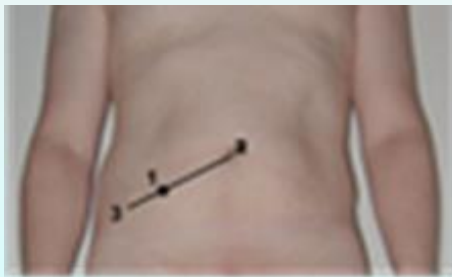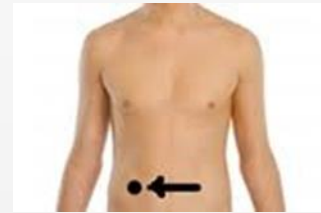


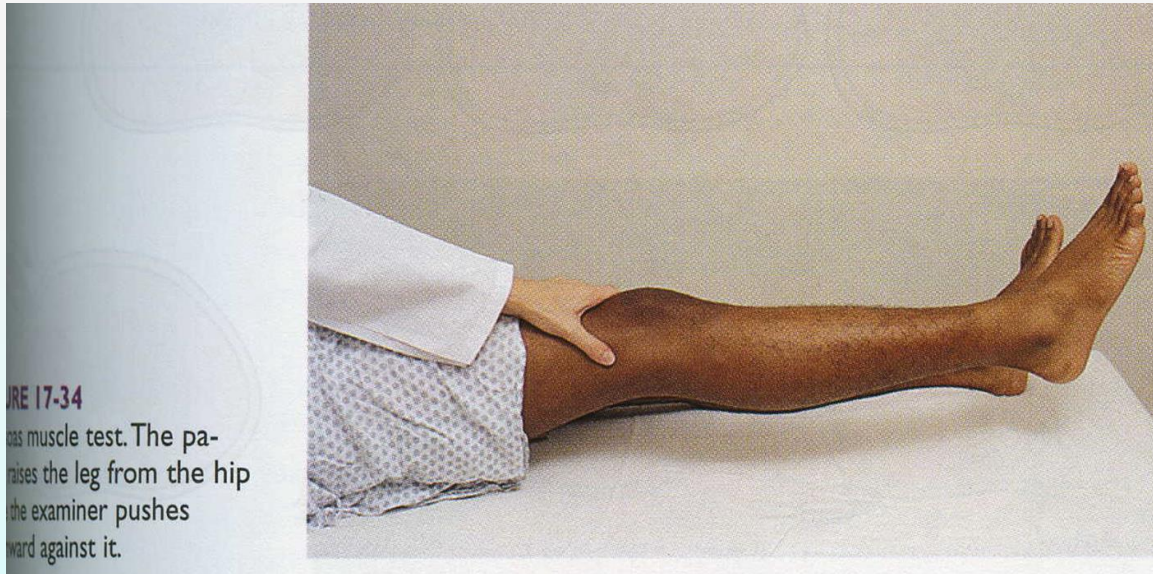


圖: Deep tenderness at McBurney's point, known as **McBurney's sign**



Psoas sign

- ◆ Place your hand above the patient's **right knee**.
- ◆ Ask the patient to flex the right hip against resistance.
- ◆ Increased abdominal pain indicates a positive psoas sign.



Obturator sign

- ◆ The examiner holds the patient's ankle with one hand and knee with the other hand. The examiner internally rotates the hip by moving the patient's ankle away from the patient's body while allowing the knee to move only inward. This is flexion and internal rotation of the hip.
- ◆ Increased abdominal pain indicates a positive obturator sign.




Figure 17-39. The iliop-
was test.

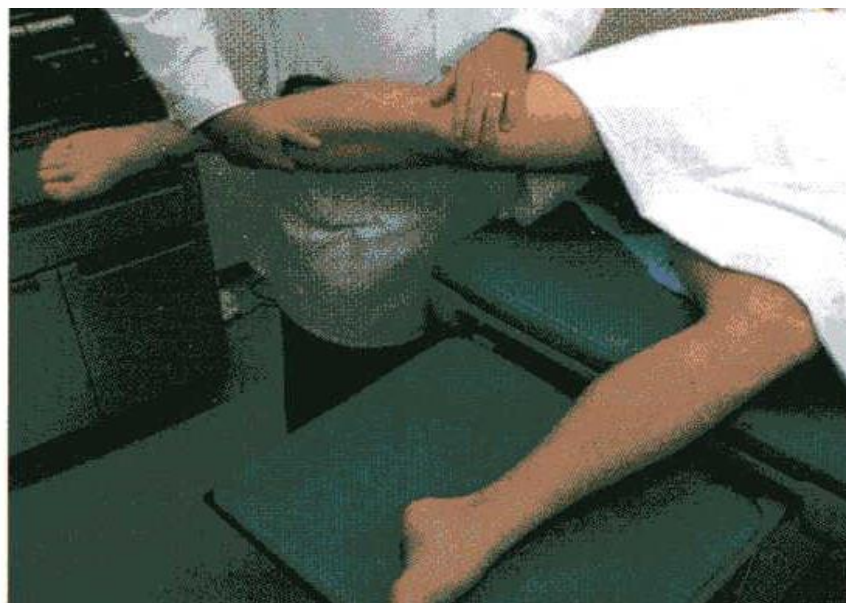
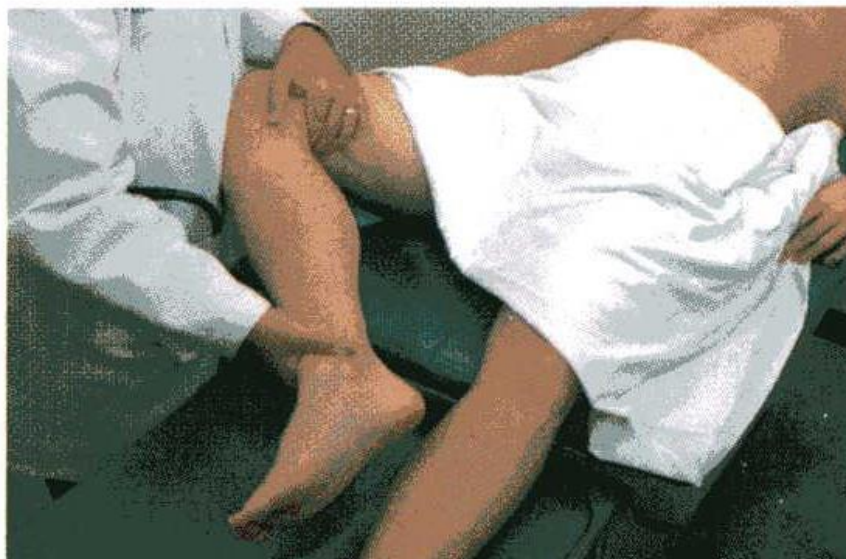
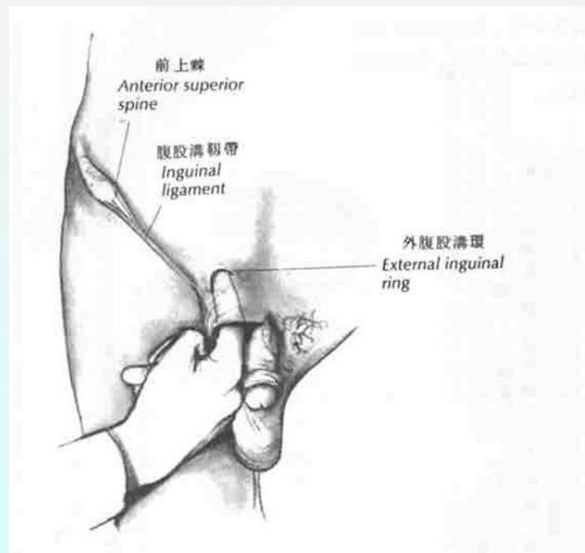
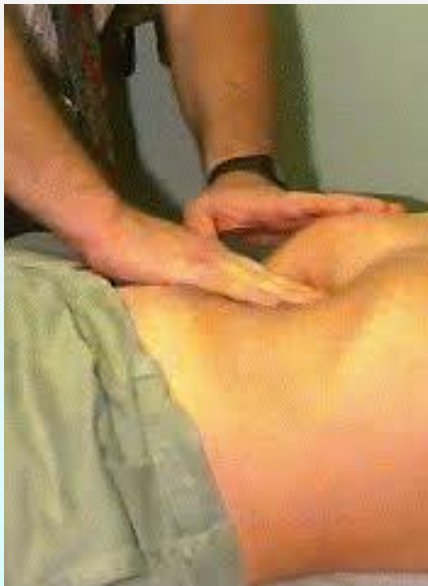

Figure 17-40. The obtura-
lor test.



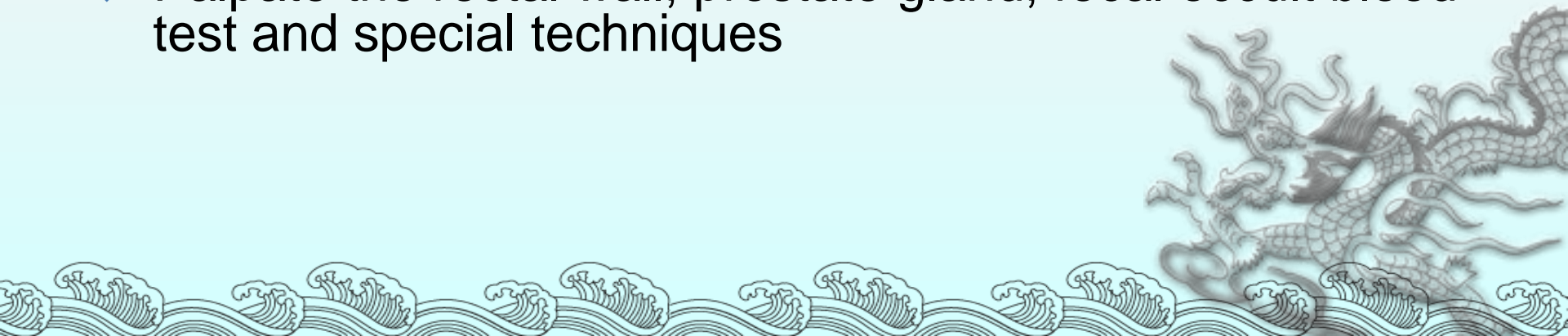
Murphy's sign and Hernia

- ◆ Asking the patient to **breathe out** and then **gently placing the hand below the costal margin** on the right side at the mid-clavicular line (the approximate location of the gallbladder).
- ◆ The patient is then instructed to inspire (**breathe in**).



Rectal examination

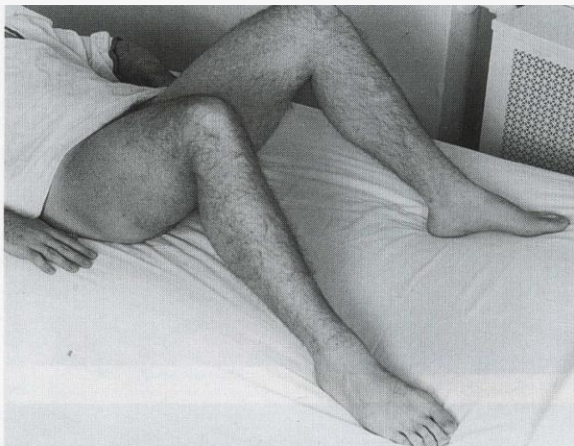
- ◆ **Digital rectal examination**: the anterior rectum has a peritoneal surface, the DRE may **reveal tenderness if peritoneal inflammation** is present
- ◆ Right hand of examiner **with index finger**
- ◆ Ask the patient **take a breath** when index finger is inserted (cold sensation must explained before this procedure)
- ◆ Palpate the rectal wall, prostate gland, fecal occult blood test and special techniques



Position

Lying on his back, with knee flexed
(Modified lithotomy position)

Left lateral prone position with right
upper leg flexed while left lower leg
semi-extended (Sim's position)



A

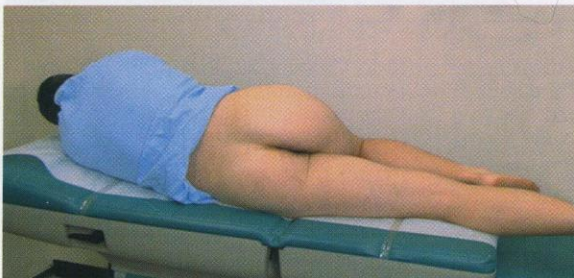

Figure 17-32. Positions for the rectal examination. A, Modified lithotomy position. B, Sims' position.

Standing, bent over the examination table

